

## **Action of *Citrullus lanatus* on the Cytoarchitecture of Testes in Wistar Rats Following Prolong Exposure to Methanolic Seeds Extract of *Carica papaya***

Nathaniel Ohiemi Amedu<sup>1\*</sup> and Ukanu Paul Idoko<sup>1</sup>

<sup>1</sup>Department of Anatomy, Kogi State University Anyigba, Kogi State, Nigeria.

### **Authors' contributions**

*This work was carried out in collaboration between both authors. Author NOA designed the study, wrote the protocol, and wrote the first draft of the manuscript. Author UPI managed the literature searches, analyses of the study performed the spectroscopy analysis and author NOA managed the experimental process. Author NOA identified the species of plant. Both authors read and approved the final manuscript.*

### **Article Information**

DOI: 10.9734/JALSI/2016/22956

#### Editor(s):

(1) Palanisamy Arulselvan, Institute of Bioscience, Universiti Putra Malaysia, Malaysia.

#### Reviewers:

(1) Sandra Maria Barbalho, School of Medicine, University of Marília, SP, Brazil.

(2) L. D. C. Peiris, University of Sri Jayewardenepura, Sri Lanka.

Complete Peer review History: <http://sciencedomain.org/review-history/15170>

**Original Research Article**

**Received 6<sup>th</sup> November 2015**  
**Accepted 2<sup>nd</sup> December 2015**  
**Published 25<sup>th</sup> June 2016**

### **ABSTRACT**

**Aim:** This study was carried out to examine the action of *Citrullus lanatus* on the cytoarchitecture and glycogen distribution in the testes of Wistar rats following prolonged exposure to methanolic seeds extract of *Carica papaya*.

**Study Design:** Eighteen adult male Wistar rats were randomly assigned into three groups of six (n=6): A, B, and C. Group A served as the control group while the other groups served as the treated groups.

**Place and Duration of Study:** This study was carried out in the Animal Holdings of the Department of Anatomy, University of Ilorin, Ilorin, Nigeria between July, 2014 and October, 2014.

**Methodology:** The Group A animals were given feed and water liberally throughout the study. Group B received 150 mg/kg/bwt/d of *Carica papaya* methanolic seeds extract intraperitoneally for 8 weeks, Group C received 150 mg/kg/bwt/d of *Carica papaya* methanolic seeds extract

\*Corresponding author: Email: [amedunathaniel@yahoo.co.uk](mailto:amedunathaniel@yahoo.co.uk)

intraperitoneally plus *Citrullus lanatus* orally for 8 weeks. The rats were sacrificed at the end of administration, histological and histochemical techniques were applied. Tissues were viewed under a light microscope.

**Results:** Generally, the seminiferous tubules as well as interstitial spaces in Group A and C appeared normal but in Group B there was degeneration of interstitial spaces and congestion of seminiferous tubules. However, glycogen distribution was the same for all the groups.

**Conclusion:** *Citrullus lanatus* has ameliorative effects on cytoarchitecture of the testes in wistar rats following prolong exposure to methanolic seeds extract of *Carica papaya*. It was also revealed that methanolic seeds extract of *Carica papaya* does not affect the glycogen distribution in testes especially at the dose used in this study.

**Keywords:** Cytoarchitecture; *Carica papaya*; *Citrullus lanatus*; glycogen; prolong.

## 1. INTRODUCTION

*Carica papaya* is a tasty fruit that is rapidly propagated in the tropics, it is believed to be a native of southern Mexico and neighbouring Central America [1]. It belong to the family of *Caricaceae* [2]. It is commonly referred to as pawpaw (UK), papaya (France), papita (India), fruta bomba (Cuba) and mamão (Brazil) [3].

Some of the active compounds of *Carica papaya* are Papain, Alkaloids, Carpaine, chymopapain, Nicotine, Caoutchone, Oleic acid [4]. The extracts of *Carica papaya* are known for medicinal uses such as nephroprotective activity [5], anti-sickling activity [6], anti-tumor activity [7], wound healing effects [8], anti-hypertensive activity [8]. The seeds are effective in treating hypercholesterolemia, diabetes mellitus and hypertension [9,10,11,12]. Despite the important medicinal uses of *Carica papaya*, there exist some unpleasant side effects of this plant such as; anti-implantation and abortifacient effects [13], antifertility [14]. High doses of aqueous extract *Carica papaya*, reduces sperm motility, decreases sperm count and viability in wistar rats [15].

Distorted cytoarchitecture and reduction in interstitial cells has been linked to infertility following administration of unripe *Carica papaya* seeds [16]. Aqueous bark extract of *Carica papaya* has deleterious effects on both the seminiferous tubules and testicular interstitium [17]. Also, severe necrosis of the germinal epithelium of the testes has been reported following administration of root extracts of *Carica papaya* [12].

*Citrullus lanatus* is a tropical plant which belongs to the family of *Cucurbitaceae*. It is grown all over South East Asia and most part of Africa [18]. It is commonly referred to as Egusi melon, egusi

watermelon, West African watermelon, dessert watermelon, cooking melon [19,20]. *Citrullus lanatus* has fleshy parts that are red, orange, yellow or white in colour depending on the variety and green outer part [21,22]. The inner red part of *Citrullus lanatus* contains large quantity of beta carotene and is a significant source of lycopene [19,18]. Lycopene is rich in antioxidant and has potential health benefits. *Citrullus lanatus* plant has bioactive compounds such as cucurbitacin, triterpenes, sterols and alkaloids [23,24].

The extracts of *Citrullus lanatus* are used for various purposes such as; protection against prostate cancer [25, 26] treatment of type 2 diabetes [27], improve blood vessel function [28] and reduction of blood pressure in hypertensive patients [29]. Others are: antimicrobial activities, antiangiogenic activity and anti-inflammatory activity [30,31]. Methanolic extracts of *Citrullus lanatus* seeds has proven to be a treatment option against lead-acetate induced oxidative stress and toxicity in testicular tissue [32].

As a result of earlier reported effects of *Carica papaya* on seminiferous tubules and testicular interstitium, this study was designed to examine the action of *Citrullus lanatus* on the cytoarchitecture and glycogen distribution in the testes of Wistar rats following prolong exposure to methanolic seeds extract of *Carica papaya*.

## 2. MATERIALS AND METHODS

Eighteen adult male Wistar rats (with an average weight of 240 g) were procured from department of anatomy, Ladoke Akintola University of Technology. The animals were acclimatized for two weeks at the animal holdings of Anatomy department, University of Ilorin, Ilorin before the commencement of the experiment. They were exposed to normal laboratory conditions of temperature, light and humidity. The rats were

fed with pelletized feeds (produced by Vital feeds, Nigeria) and water *ad libitum*. The animals were given adequate care in accordance with the Principle of Laboratory and Animal Care prepared by the National Academy of Sciences and published by the National Institute of Health [33]. All the rats were carefully assessed and screened at the end of the acclimatization period. The investigation was conducted in accordance with the principles and guidelines for animal research.

## 2.1 Plant Materials and Extraction

Ripe *Carica papaya* was bought from Oja Oba market, Ilorin and it was authenticated at the Pharmacology department of university of Ilorin. The seeds were removed and air dried for 7 days. There were later pounded into powdery form using mortar and pestle. 80.65 g of the sample was immersed in 300 mL of methanol for 48 hours after which the solution was sieved and evaporated to dryness at 30°C. It was then weighed and refrigerated until use.

The *Citrullus lanatus* used was bought from Oja Oba market, Ilorin and it was authenticated at the Pharmacology department of university of Ilorin. The rind was separated from its inner part. The inner red part was chopped into small pieces then blended with an electronic blender. The juice was later concentrated using Rotary evaporator and then stored in a refrigerator at 4°C until use.

## 2.2 Experimental Design

Eighteen adult male rats were randomly divided into three (3) groups of six (6) rats each;

*Group A* (control): received only distilled water.

*Group B*: received methanolic seeds extract of *Carica papaya* (intraperitoneally) 150 mg/kg/bwt/d for 8 weeks.

*Group C*: received methanolic seeds extract of *Carica papaya* (intraperitoneally) 150 mg/kg/bwt/d for 8 weeks + *Citrullus lanatus* mix in their drinking water throughout the experiment.

## 2.3 Termination of Treatment

At the end of 8 weeks, the rats were anaesthetized by cervical dislocation and then sacrificed. The testes were collected and immediately fixed in formal saline before embedding in paraffin wax. Sections were prepared using an electric rotatory microtome

(YD-355AT) at 5 µm. The sections were stained with haematoxylin and eosin (H & E) stain, Periodic Acid-Schiff reaction (using the method of McManus, 1946) and feulgen DNA reaction (using the method of Feulgen and Rossenbeck, 1924) [34]. The stained sections were then viewed under the light microscope.

## 3. RESULTS

Plate 1. Shows transverse sections of the testes stained with H & E. Group A and Group C appeared normal. The interstitial space (yellow arrow) and seminiferous tubules with spermatocytes (Red arrows) appear intact. However Group B shows disorganized or degenerated interstitial space (Yellow arrows) and congested seminiferous tubules (Red arrows).

Plate 2 Shows transverse sections of the testes stained through feulgen DNA reaction. Group A and Group C appeared deeply stained for DNA in testicular cells (yellow arrows). However Group B appeared lightly stained for DNA in testicular cells (yellow arrows).

Plate 3 Shows transverse sections of the testes stained through PAS reaction. All the groups appeared deeply stained for PAS in testicular cells (yellow arrows).

## 4. DISCUSSION

It has been reported that seed extract of *Carica papaya* causes infertility in male albino rats [14,35]. However, lycopene is believed to be a treatment for idiopathic infertility [36]. *Citrullus lanatus* is one of many plants that has lycopene content [18]. Lycopene is rich in antioxidant and has potential health benefits. Lycopene utilizes redox defence mechanism to fight against free radicals that could cause infertility [36]. Testes is believed to be an organ that store lycopene in human [36].

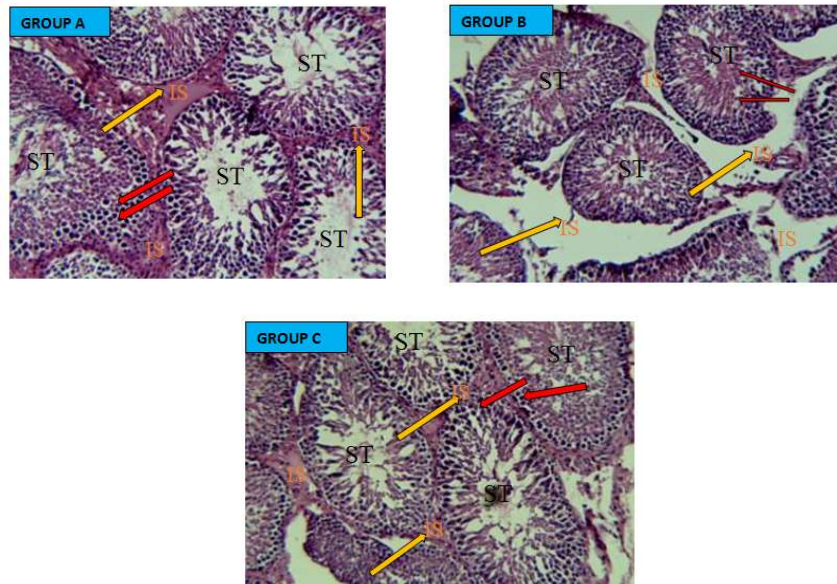
The testes is a part of male reproductive system, it has a dual function which is to produce spermatozoa and secrete testosterone [37]. Testosterone is a steroid hormone that belong to the androgen group. It is secreted primarily in the Leydig cells of the testes through stimulation of luteinizing hormone (LH) [38].

Among the structures that make up the testes are seminiferous tubules which produces the male reproductive cells and interstitial cells which occupy much of the space between the

seminiferous tubules. The basal lamina of the testes is lined externally by myoid cells [37].

The present study (in Plate 1) shows that the interstitial space and seminiferous tubules with spermatocytes appeared normal in Group A and Group C. However Group B shows degenerated

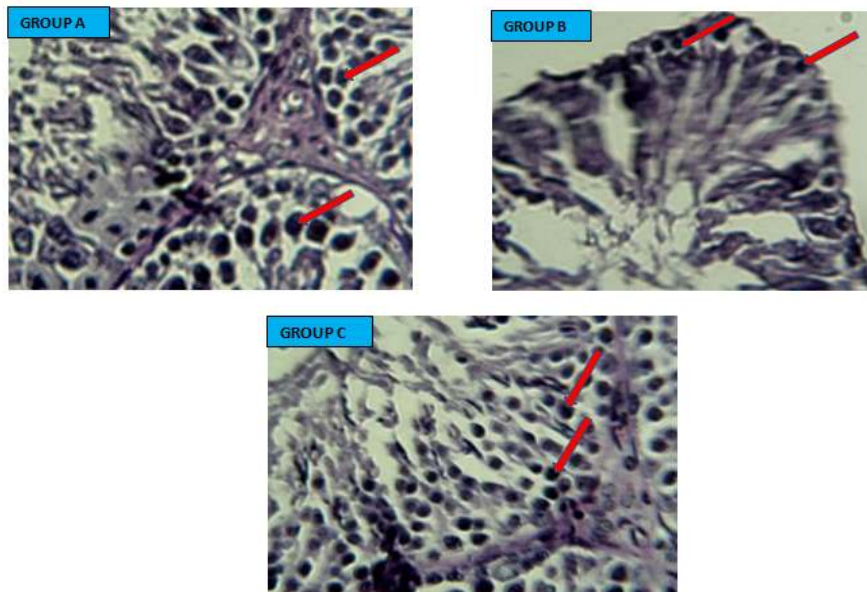
or disorganized interstitial space and congested seminiferous tubules. The degenerated interstitial space and congested seminiferous tubules seen in Group B was ameliorated in Group C possibly due to *Citrullus lanatus* administered which contains lycopene. Earlier findings supported this observation [32,17].



**Plate 1. Transverse sections of rat testes, H & E x 100. Yellow arrows point to the interstitial space with cells, Red arrows point to the seminiferous tubules**  
 ST- Seminiferous Tubules; IS- Interstitial space



**Plate 2. Transverse sections of rat testes, Feulgen DNA x 400. Yellow arrows point to the DNA stain intensity of Testicular cells. Group A is the control while B & C are the treated groups**



**Plate 3. Transverse section of rat testes, PAS  $\times$  400. Red arrows point to the staining intensity of PAS on testicular cells. Group A is the control while B & C are the treated groups**

The result from Plate 2 revealed numerous testicular cells stained with high intensity for DNA in Group A and Group C. however Group B section stain with less intensity for DNA. Also the result from Plate 3 revealed deeply stained PAS sections for all the Groups. This indicates that the glycogen present in the testes are high and the same in all the groups [34].

## 5. CONCLUSION

In conclusion, this present work has shown that *Citrullus lanatus* has ameliorative effects on cytoarchitecture of the testes in wistar rats following prolong exposure to methanolic seeds extract of *Carica papaya*. It has also revealed that *Carica papaya* methanolic seeds extract does not affect the glycogen distribution in the testes especially at the dose used in this study. Further studies is recommended to build on the findings of this work.

## ETHICAL APPROVAL

All authors hereby declare that "Principles of laboratory animal care" (NIH publication No. 85-23, revised 1985) were followed, as well as specific national laws where applicable. All experiments have been examined and approved by the appropriate ethics committee. All authors hereby declare that all experiments have been examined and approved by the appropriate ethics committee and have therefore been

performed in accordance with the ethical standards laid down in the 1964 Declaration of Helsinki.

## ACKNOWLEDGEMENTS

We wish to express our sincere appreciation to James Amedu for sponsoring this study.

## COMPETING INTERESTS

Authors have declared that no competing interests exist.

## REFERENCES

1. Aradhya MK, Manshardt RM, Zee F, Morden CW. A phylogenetic analysis of genus *Carica* L. (Cariceae) based on the restriction of fragment length variation in a cpDNA intergenic spacer region. Online; 1999.
2. OECD. Consensus document on the biology of (*Carica papaya*). Oecd environment, health and safety publications, series on harmonisation of regulatory oversight in biotechnology NO 33, France, available online; 2005.
3. The biology of *Carica papaya* L. Australian Government office of gene technology regulator. Version 2; 2008.
4. Duke J. *Carica papaya* L. Caricaceae; 2007.
5. Olagunju JA, Adeneye AA, Fagbohunka-Bisuga NA, Ketiku AO, Benebo AS,



- Olufowobi OM, Adeoye AG, Alimi MA, Adeleke AG. Nephroprotective activities of the aqueous seed extract of *Carica papaya* Linn. In carbon tetrachloride induced renal injured Wister rats: A dose and time dependent study. *Biology and Medicine*. 2009;1(1):11-19.
6. Oduola T, Adeniyi FAA, Ogunyemi EO, Bello IS, Idowu TO. Anti-sickling agent in an extract of unripe pawpaw (*Carica papaya*): Is it real? *Afri J Biotech*. 2006;5(20):1947-1949.
  7. Otsuki N, Dang NH, Kumagai E, Kondo A, Iwata S, Morimoto C. Aqueous extract *Carica papaya* leaves exhibits anti-tumor activity and immunomodulatory effects. *Journal of ethnopharmacology*. 2010;127:760-767.
  8. Mahmood AA, Sidik K, Salmah I. Wound healing activity of *Carica papaya* L. aqueous extract in rats. *International Journal of Molecular Medicine and Advance Science*. 2005;1(4):398-401.
  9. Koffi N, Solange TM, Emma AA, Noel ZG. Ethnobotanical study of plants used to treat arterial hypertension, in traditional medicine by abbey and Krobou populations of agboville. *European Journal of Scientific Research*. 2009;35(1):85-98.
  10. Gill LS. *Carica papaya* L. In: *Ethno-medicinal uses of plants in Nigeria*; 1992.
  11. Ayoola PB, Adeyeye A. Phytochemical and nutrient evaluation of *Carica papaya* (pawpaw) leaves. *IJRRAS*. 2010;5(3):325-328.
  12. Nwaehujor CO, Ode JO, Ekwere MR, Udegbonam RI. Anti-fertility effects of fractions from *Carica papaya* (Pawpaw) Linn. methanol root extract in male Wistar rats. *Arabjc*. 2014;10:018.
  13. Pokhartar RD, Saraswat RT, Kotkar S. Survey of plants having anti-infertility activity from Western Ghat area of Maharashtra State. *Journal of Herbal Medicine and Toxicology*. 2010;4(2):71-75.
  14. Lohiya NK, Manivannan B, Garg S. Toxicological investigations on the methanol sub-fraction of the seeds of *Carica papaya* as male contraceptive in albino rats. *Reproductive toxicology*. 2006;22:461-468.
  15. Verma RJ, Nambiar D, Chinoy NJ. Toxicological effects of *Carica papaya* seed extract on spermatozoa of mice. *Journal of applied toxicology*. 2006;26:533-535.
  16. Igiri, AO, Mesembe EO, Udoaffah G, Eluwa MA, Morah N. Antifertility effect of unripe pawpaw seed. *J. Anatomical Soc. Eastern Nigeria Book Abstracts*. 2003;9.
  17. Kusemiju TO, Osinubi AA, Noronha CC, Okanlawon AO. Effect of aqueous bark extract of *Carica papaya* on testicular histology in Sprague Dawley rats. *Nig Q J Hosp Med*. 2010;20(3):133-7.
  18. Mandel H, Levy N, Izkovitch S, Korman SH. Elevated plasma citrulline and arginine due to consumption of *Citrullus vulgaris* (watermelon). *Berichte Der Deutschen chemischen Gesellschaft*. 2005;28(4):467–472.
  19. Rhodes B, Zhang XP. Hybrid seed production in watermelon. In: Basra, A.S. (Editor). *Hybrid seed production in vegetables: Rationale and methods in selected crops*. Food Products Press, New York. 1999;69–88.
  20. Erhirhie EO, Ekene NE. Medicinal values on *Citrullus lanatus* (Watermelon): Pharmacological review. *International Journal of Research in Pharmaceutical and Biomedical Sciences*. 2013;4(4):1305-1312.
  21. Laghetti G, Hammer K. The corsican citron melon [*Citrullus lanatus* (Thunb.) Matsumura & Nakai subsp. lanatus var. citroides (Bailey) Mansf. Ex Greb.] a traditional and neglected crop. *Genetic Resources and Crop Evolution*. 2007;54:913–916.
  22. Mabberley DJ. *Mabberley's Plant-Book. A portable dictionary of plants, their classification and uses*. Cambridge University Press; 2008.
  23. Yuan G, Wahlqvist ML, He G, Yang M, Li D. Natural products and anti-inflammatory activity. *Asia Pac. J. Clin. Nutr*. 2006;15:143.
  24. Erukainure OL, Oke OV, Daramola AO, Adenekan SA, Umanhonlen EE. *Pakistan Journal of Nutrition*. 2010;9(8):806-809.
  25. Jian Le. Lee, Andy H. Binns, Colin W. Relationship between tea, lycopene consumption and prostate cancer risk. *Asia pacific J. Clin Nutr*. 2007;16(1):453-457.
  26. Adesanya A. Olamide, Olaseinde O. Olayemi, Oguntayo O. Demetrius, Otulana J. Olatoye, Adefule A. Kehinde. Effects of methanolic extract of *Citrullus lanatus* seed on experimentally induced prostatic hyperplasia. *European Journal of Medicinal Plants*. 2011;1(4):171-179.
  27. Lucotti. Beneficial effect of a long term oral L-arginine treatment added to a

- hypocaloric diet and exercise training program in obese, insulin-resistant type diabetic patients. *Am J Physiol Endocrinol.* 2006;291(5).
28. Patil B. Watermelon may have Viagra-effect. *Science Daily*; 2010.
29. Figueroa A. Effects of watermelon supplementation on aortic blood pressure and wave reflection in individuals with Prehypertension: Pilot study. *Am J Hypertens.* 2011;24(1):40-4.
30. Loiy Elsir Ahmed Hassan, Hasnah Mohd Sirat, Sakina M. Ahemd Yagi, Waleed S. Koko, Siddig Ibrahim Abdelwahab. *In vitro* antimicrobial activities of chloroformic, hexane and ethanolic extracts of *Citrullus lanatus* var. *citroides* (Wild melon). *Journal of Medicinal Plants Research.* 2011;5(8):1338-1344.
31. Madhavi P, Kamala V, Habibur R. Hepatoprotective Activity of *Citrullus Lanatus* Seed Oil on CCl<sub>4</sub> Induced Liver Damage in Rats. *Scholars Academic Journal of Pharmacy (SAJP).* 2012;1(1):30-33.
32. Onyeso G, Nkpaa KW, Nwaka E. Ameliorative potential of methanolic extract of *Citrullus lanatus* seeds on the sperm parameters, testosterone level and testicular cytoarchitecture of male albino rats induced with lead acetate. *BJPR.* 2015;6(1):35-43.
33. National Institute of Health Guide for the Care and Use of Laboratory Animals; DHEW Publication (NIH). Revised office of science and health. Reports DRR/NIH Bethesda USA; 1985.
34. Bancroft JD, Gamble M. Theory and practice of histological techniques. Elsevier. 6<sup>th</sup> Ed; 2008.
35. Lohiya NK, Goyal RB, Jayaprakash D, Ansari AS, Sharma S. Antifertility effects of aqueous extract of *Carica papaya* seeds in male rats. *Planta Med.* 2005;60:400-202.
36. Narmada PG, Rajeev Kumar. Lycopene therapy in idiopathic male infertility – a preliminary. Report. *International Urology and Nephrology.* 2002;34:369-372.
37. Junqueira LC, Carneiro J. Basic histology; Text and Atlas. 11<sup>th</sup> Ed; 2005.
38. Changamma C, Govardhan NA. Hormonal changes in *Piper betel* linn. Leaf stalk Extract administered male albino rats. *World Journal of Pharmaceutical Research.* 2014;3(4):1953-1959.

© 2016 Amedu and Idoko; This is an Open Access article distributed under the terms of the Creative Commons Attribution License (<http://creativecommons.org/licenses/by/4.0>), which permits unrestricted use, distribution, and reproduction in any medium, provided the original work is properly cited.

Peer-review history:  
The peer review history for this paper can be accessed here:  
<http://sciencedomain.org/review-history/15170>