



Unveiling Type 4A Choledochal Cyst a Congenital Anomaly Presenting in Adulthood: A Surgical Challenge

Shrikanta Biswas^{a++*}

^a SCB Medical College and Hospital, Cuttack, Odisha, India.

Author's contribution

The sole author designed, analysed, interpreted and prepared the manuscript.

Article Information

Open Peer Review History:

This journal follows the Advanced Open Peer Review policy. Identity of the Reviewers, Editor(s) and additional Reviewers, peer review comments, different versions of the manuscript, comments of the editors, etc are available here: <https://www.sdiarticle5.com/review-history/119495>

Case Report

Received: 05/04/2024

Accepted: 01/07/2024

Published: 05/07/2024

ABSTRACT

Rare congenital biliary tree malformations known as choledochal cysts can have a substantial negative impact on morbidity and mortality if they are not detected and treated promptly. The dilatation of either the intrahepatic or extrahepatic bile ducts, or both, is a characteristic of these cysts. Asian populations are more likely to have choledochal cysts; in Japan, the frequency is as high as one in per 1000 live births. There are 5 subtypes of choledochal cyst and in adults type 4 is the most common. Here we report a case of a 52-year-old lady who presented with vague abdominal pain and on evaluation was incidentally found to have a choledochal cyst type 4A. The patient underwent excision of the extrahepatic hugely dilated choledochal cyst with cholecystectomy and reconstruction was done by Roux-en-Y hepaticojejunostomy to the confluence of the right and left hepatic duct at the hilum.

⁺⁺ Resident Doctor;

^{*}Corresponding author: E-mail: shrikantaroni95@gmail.com;

Cite as: Biswas, Shrikanta. 2024. "Unveiling Type 4A Choledochal Cyst a Congenital Anomaly Presenting in Adulthood: A Surgical Challenge". *Asian Journal of Case Reports in Surgery* 7 (2):352-59. <https://journalajcrs.com/index.php/AJCRS/article/view/549>.

Keywords: Choledochal cyst; todani; hepaticojejunostomy; liver transplant; hepatectomy; Roux-en-Y; choledochocele; diverticulum; pancreatic divisum.

ABBREVIATIONS

CECT : Contrast Enhanced Computed Tomography
IHBR : Intrahepatic Biliary Radicles
MRCP :Magnetic Resonance Cholangiopancreatography
CBD : Common Bile Duct

1. INTRODUCTION

“Choledochal cysts are focal or diffuse dilatations of the biliary tree, and aside from biliary atresia, they are the most common congenital abnormality of the biliary tree. Choledochal cysts can occur as single or multiple cysts throughout the extrahepatic or intrahepatic bile ducts. The incidence of choledochal cysts varies significantly throughout the world. Choledochal cysts appear to be most common in Asian countries with an estimated incidence of 1 in 1000 live birth. Biliary cysts are 4 times more common in women compared with men. Approximately 80% of choledochal cysts are diagnosed in children, and 20% of cases present in adults. The classic triad of presentation of a choledochal cyst is a female child with jaundice, abdominal pain, and right upper quadrant abdominal mass. This triad is found in only a minority of children at the time of presentation. In

adults, abdominal pain and recurrent cholangitis are the most common” [1].

“Ultrasonography is the most common first-line imaging tool. when choledochal cyst disease is suspected on imaging, visualization of the pancreatic, intrahepatic, and extrahepatic ductal anatomy is required. Magnetic resonance cholangiopancreatography (MRCP) has become the non-invasive procedure of choice for the diagnosis of choledochal cyst” [1].

This is a case report of a female presenting to surgery opd with a diagnosis of Todani 4A choledochal cyst.

2. CASE REPORT

A 52-year-old female patient from Cuttack Odisha India presented with the chief complaint of Pain in her upper abdomen and vomiting after taking a meal. She reported that it began a month ago with mild to moderate epigastric pain of the colic type, aggravated after feeding, which persisted even after taking analgesics. Pain is associated with vomiting non-bilious undigested food material within 15-20 minutes of taking food. Vomiting was not seen after taking water or clear liquid. She didn't have any fever or chills, jaundice, anorexia, or recent weight loss. There was a history of jaundice 2year ago that subsided on its own.

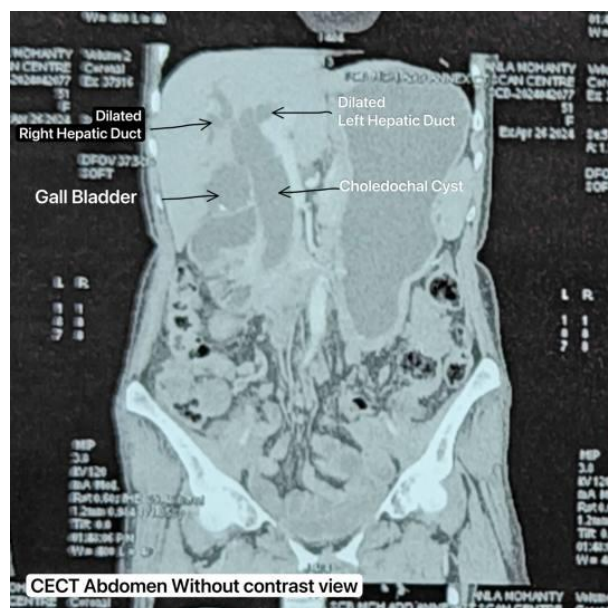


Fig. 1. CECT Abdomen and pelvis non-contrast image showing: Dilated Right and Left Hepatic Duct (IHBR), Gall Bladder and Choledochal cyst

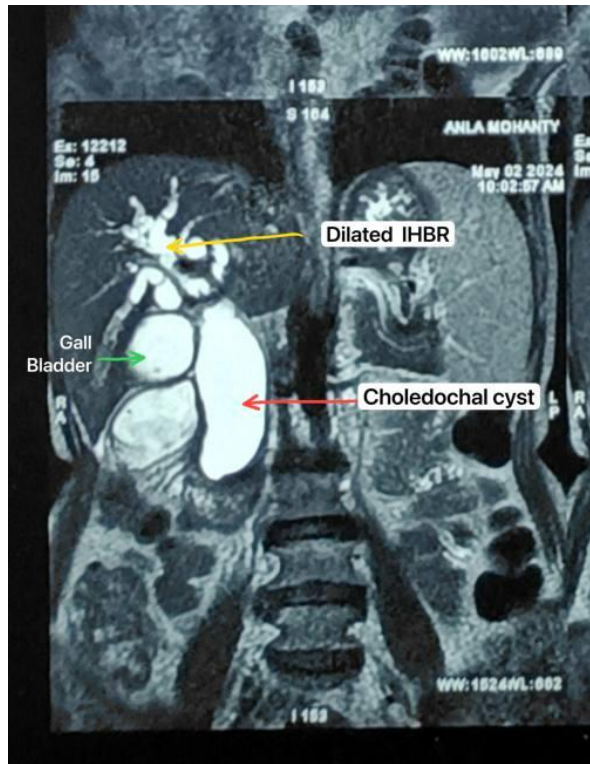


Fig. 2. CECT Abdomen and Pelvis contrast image: Dilated Intra hepatic biliary radicle, Gall Bladder, Choledochal cyst

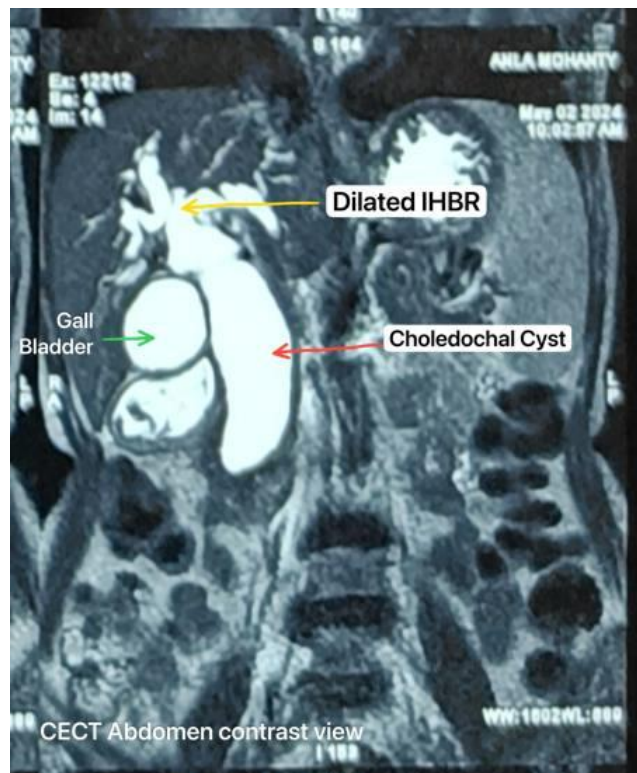


Fig. 3. CECT Abdomen and Pelvis showing: Dilated Intra hepatic biliary radicle, Gall Bladder, Choledochal cyst

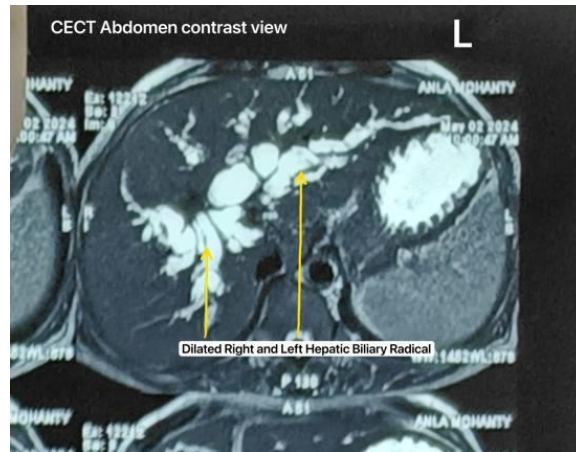


Fig. 4. CECT Abdomen and Pelvis showing: Dilated Intra hepatic biliary radicle

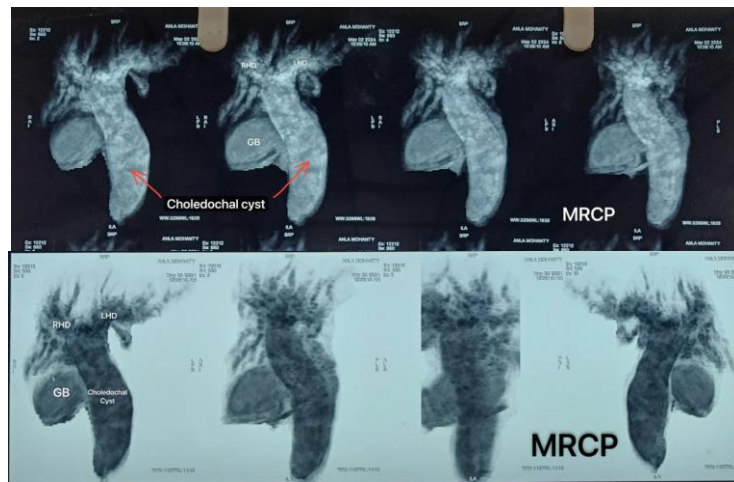


Fig. 5. MRCP showing: Dilated Right and Left Hepatic Duct (IHBR), Gall Bladder and Choledochal cyst

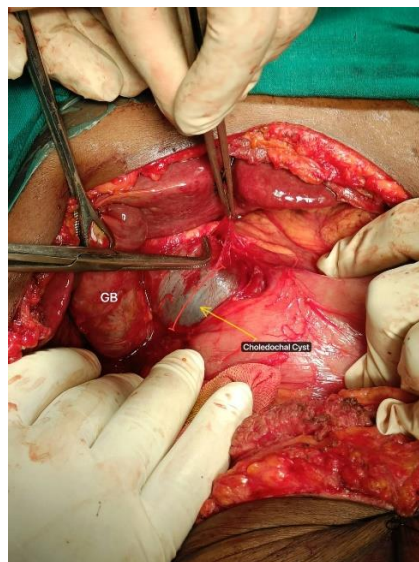


Fig. 6. Intra OP Picture showing: Dilated Choledochal cyst (yellow arrow), 30 mm thickness denoted by (red marking) and Gall Bladder (GB)

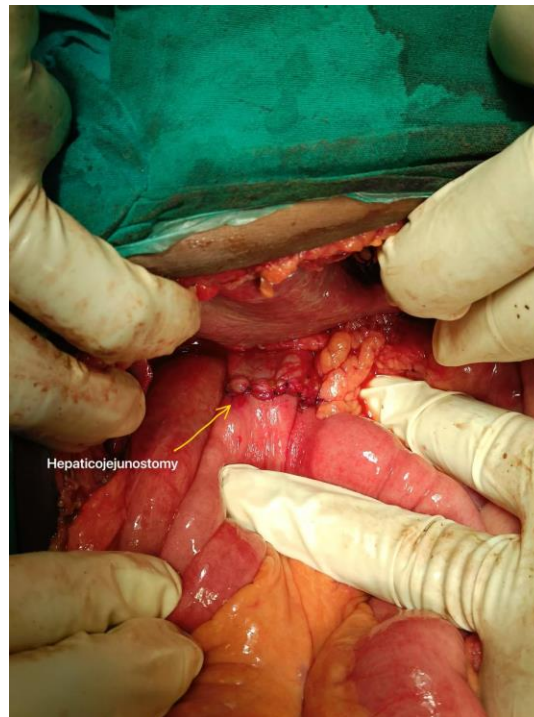


Fig. 7. Intra OP Picture showing: Hepaticojejunostomy (yellow arrow)

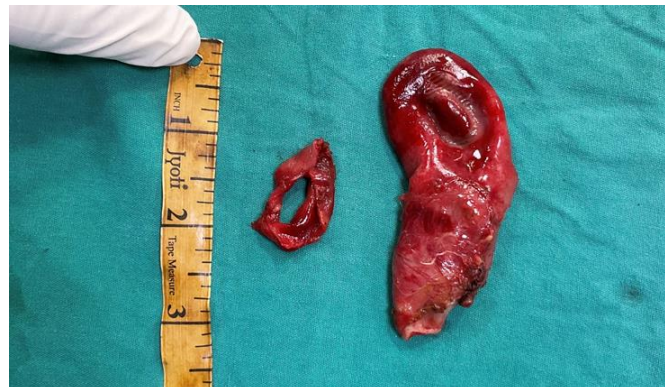

Fig. 8. showing: Resected Choledochal cyst (Left) and Gall Bladder (Right)

She underwent abdominal ultrasound that revealed cholelithiasis with intra and extra-hepatic bile duct dilatation and CECT (Figs.1,2,3,4) revealed cholelithiasis with 30 mm dilated CBD with gradual narrowing at the distal end, bilobar IHBR dilated then MRCP (Fig. 5) was done come as todani Type 4A (Fig. 9) choledochal cyst with cholelithiasis. After two weeks the patient underwent laparotomy and found hugely dilated CBD identified as Choledochal cyst (Fig. 6) underwent for cholecystectomy followed by Roux-en-Y end-lateral hepatic jejunostomy (Fig. 7) and resected specimen sent for Histopathological examination (Fig. 8). The postoperative

evolution was satisfactory, being discharged on the ninth postoperative day after surgery, being followed every monthly for 1 year without evidence of pain recurrence or complications.

3. DISCUSSION

“Choledochal cysts are rare congenital abnormalities of the biliary system characterized by cystic dilatation of the bile ducts. The Todani classification system categorizes choledochal cysts into five main types based on the location and extent of the cystic dilatation” [1,2,3]. Todani Classification [3].

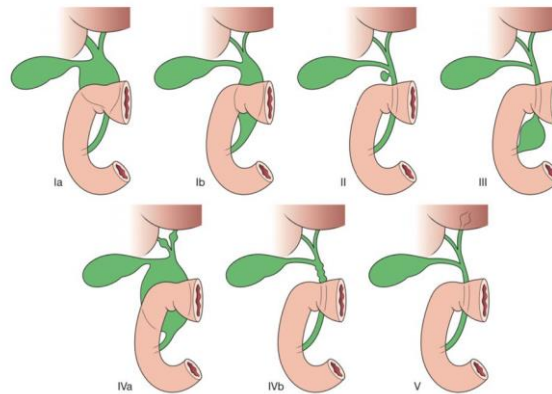


Fig. 9. Todani Classification [4]

choledochal cyst - type I:

- account for 80-90% of all bile duct cysts
- characterized by fusiform dilatation of the extrahepatic bile duct
- a subclassification has been proposed
 - **Ia:** dilatation of extrahepatic bile duct (entire)
 - **Ib:** dilatation of extrahepatic bile duct (focal segment)

Theorized to form as the result of reflux of pancreatic secretions into the bile duct via an anomalous pancreaticobiliary junction. Some believe them to arise from ductal plate anomalies.

Type II:

Also known as a bile duct diverticulum:

- account for 3% of all bile duct cysts
- saccular out pouchings, representing true diverticula, arise from the supraduodenal extrahepatic bile duct or the intrahepatic bile ducts

Type III:

Also known as a choledochocele

- account for 5% of all bile duct cysts
- represent protrusion of a focally dilated, intramural segment of the distal common bile duct into the duodenum
- believed to be analogous to the Santorinicele, which is sometimes seen in those with pancreas divisum

Choledochoceles may be successfully managed with endoscopic sphincterotomy, surgical excision, or both, in symptomatic patients.

Type IV:

Multiple communicating intra- and extrahepatic duct cysts:

- second most common type of bile duct cysts (10%)
- subdivided into subtypes:
 - **type IVa:** fusiform dilatation of the entire extrahepatic bile duct with extension of dilatation to the intrahepatic bile ducts
 - **type IVb:** multiple cystic dilations involving only the extrahepatic bile duct

Type V:

Also known as Caroli disease, which is a rare form of congenital biliary cystic disease manifested by cystic dilations of intrahepatic bile ducts. Association with benign renal tubular ectasia and other forms of renal cystic disease.

Although type I cysts are the most common in patients of all ages, type IVA cysts are more prevalent in adults [5] Our case is consistent with a Type IV A choledochal cyst.

The clinical features of choledochal cysts in adults are characterized by a distinct presentation compared to children. Adults are more likely to present with abdominal pain (98% vs. 76.2%) and less frequently with jaundice (11.6% vs. 31.9%) without vomiting or a history of jaundice without any fever or chills [6]. They are also more associated with neoplasms (21.2% vs. 21.0%) and stone disease. The symptoms vary according to the type of cyst, with jaundice mainly observed in type I and IV cysts. The diagnosis is often made in

adulthood due to the rarity of the condition, and it is often associated with complications such as anastomotic stricture, cholangitis, biliary calculi, and biliary tract malignancy [7,8].

“Although ultrasound is the best initial method for evaluating the entire intrahepatic and extrahepatic biliary system and gallbladder, it may not always be able to precisely identify that the cyst originates in the bile duct, especially larger cysts as in our case” [9]. “In this case, the presence of intrahepatic biliary dilatation adds an important clue to the diagnosis of choledochal cyst. MRCP is the current gold standard in the imaging of choledochal cysts” [10].

“The extent of the resection in type IV A cysts is controversial. Clearly, when the intrahepatic cysts are widespread, they cannot be excised; however, when the intrahepatic disease is localized, it would seem reasonable to perform the relevant partial hepatectomy” [11]. For the same reason, we excised only the extrahepatic portion of choledochal cyst and biliary-enteric anastomosis was done through Roux-en-Y hepaticojejunostomy at the level of the hilum.

4. CONCLUSION

In conclusion, type IV-A choledochal cysts may present as cystic dilatation in both intrahepatic segments more than 20mm in diameter and huge size of CBD more than 30mm, creating a diagnostic dilemma. To make a firm diagnosis and create a surgical excision strategy for the cyst, MRCP is strongly advised. Since it is not possible to remove the entire cyst due to bilateral intrahepatic ductal dilatation, extrahepatic excision of the cyst is the preferred course of treatment, and six-month follow-ups are crucial.

DISCLAIMER (ARTIFICIAL INTELLIGENCE)

I, Dr. Shrikanta Biswas hereby declare that NO generative AI technologies such as Large Language Models (ChatGPT, COPILOT, etc) and text-to-image generators have been used during writing or editing of manuscripts.

CONSENT

As per international standards or university standards, patient(s) written has been collected and preserved by the author(s).

ETHICAL APPROVAL

As per international standards or university standards written ethical approval has been collected and preserved by the author.

COMPETING INTERESTS

Author has declared that no competing interests exist.

REFERENCES

1. Zinner MJ, Ashley SW. Maingot's abdominal operations. 13th edition. McGraw Hill Professional; 2018. Available:http://books.google.ie/books?id=e5p7DwAAQBAJ&q=maingots+abdominal+operations+13th+e&dq=maingots+abdominal+operations+13th+e&hl=&cd=1&source=gbs_api
2. Available:<https://onlinelibrary.wiley.com/doi/10.1002/ccr3.6907>
3. O'Connell PR, McCaskie AW, Williams NS. Bailey & love's short practice of surgery, 27th Edition. CRC Press; 2018. Available:http://books.google.ie/books?id=DDgPEAAAQBAJ&printsec=frontcover&dq=bailey+and+love+short+practice+of+surgery&hl=&cd=2&source=gbs_api
4. Todani T, Watanabe Y, Narusue M, Tabuchi K, Okajima K. Congenital Bile Duct Cysts. Am J Surg. 1977;134(2): 263-9. DOI: 10.1016/0002-9610(77)90359-2 - Pubmed
5. Soreide K, Korner H, Havnen J, et al. Bile duct cysts in adults. Br J Surg. 2004;91:1538–1548.
6. Nahle AA, Hamdar H, Essayli D, Awada R, Martini N, Kanbar M, Dalati H. Acute jaundice as a manifestation of midgut volvulus in a 6-year-old child: A case report. Journal of Pediatric Surgery Case Reports. 2023;96:102697. Available:<https://doi.org/10.1016/j.epsc.2023.102697>
7. Available:<https://jamanetwork.com/journals/jamasurgery/fullarticle/212375>
8. Available:<https://www.intechopen.com/chapters/83025>
9. Kim OH, Chung HJ, Choi BG. Imaging of the choledochal cyst. Radiographics. 1995;15:69–88.

10. Metcalfe MS, Wemyss-Holden SA, Maddern GJ. Management dilemmas with choledochal cysts. *Arch Surg.* 2003;138:333–339.
11. Metcalfe MS, Wemyss- Holden SA, Maddern GJ. Management dilemmas with choledochal cysts. *Arch Surg.* 2003;138:333–339.

Disclaimer/Publisher’s Note: The statements, opinions and data contained in all publications are solely those of the individual author(s) and contributor(s) and not of the publisher and/or the editor(s). This publisher and/or the editor(s) disclaim responsibility for any injury to people or property resulting from any ideas, methods, instructions or products referred to in the content.

© Copyright (2024): Author(s). The licensee is the journal publisher. This is an Open Access article distributed under the terms of the Creative Commons Attribution License (<http://creativecommons.org/licenses/by/4.0>), which permits unrestricted use, distribution, and reproduction in any medium, provided the original work is properly cited.

Peer-review history:

The peer review history for this paper can be accessed here:
<https://www.sdiarticle5.com/review-history/119495>