

## Silent Myocardial Infarction Due to Kounis Syndrome

Oguz Eroglu<sup>1\*</sup>, Vedat Simsek<sup>2</sup>, Mustafa Koksal<sup>1</sup> and Turgut Deniz<sup>1</sup>

<sup>1</sup>Department of Emergency Medicine, Kirikkale University, Faculty of Medicine, Kirikkale, Turkey.

<sup>2</sup>Department of Cardiology, Kirikkale University, Faculty of Medicine, Kirikkale, Turkey.

### Authors' contributions

This work was carried out in collaboration between all authors. Author OE, wrote the draft of the manuscript. Authors VS, MK, TD managed the literature searches. Authors OE, VS designed the figures, managed literature searches and contributed to the correction of the draft. Authors OE, VS provided the case, the figures and supervised the work. All authors read and approved the final manuscript.

### Article Information

DOI: 10.9734/BJMMR/2016/22468

#### Editor(s):

(1) Vijay K. Sharma, Division of Neurology, Yong Loo Lin School of Medicine, National University of Singapore, National University Hospital, Singapore.

#### Reviewers:

- (1) Lucilene Delazari dos Santos, Sao Paulo State University, Brazil.  
(2) Nicholas K. Kounis, University of Patras, Greece.  
(3) Anonymous, Government Medical College and Hospital, Chandigarh, India.  
(4) Suzana de Albuquerque Paiva, Pontificia Universidade Catolica de Minas Gerais, Brazil.  
(5) Aleksandra Nitecka-Buchta, Medical University of Silesia, Poland.  
Complete Peer review History: <http://sciencedomain.org/review-history/12844>

Case Study

Received 2<sup>nd</sup> October 2015  
Accepted 21<sup>st</sup> December 2015  
Published 31<sup>st</sup> December 2015

### ABSTRACT

Bee stings can cause mortal anaphylactic reactions, which are also precursors to some other mortal events. Kounis syndrome (KS), or allergic myocardial infarctions, are well known concomitant events with every type of allergic reaction. KS should be considered in all patients with allergic events and concomitant chest pain admitted to emergency rooms. The clinical symptoms may not always be clear in these cases. The symptom of chest pain may not be seen in some mono- and poli-neuropathic conditions, particularly in diabetes, transplantation and drug user patients. We present a patient with KS secondary to bee sting.

*Keywords: Kounis syndrome; bee sting; lacking chest pain; electrocardiography.*

\*Corresponding author: E-mail: [oguzeroglu@kku.edu.tr](mailto:oguzeroglu@kku.edu.tr);

## 1. INTRODUCTION

The rate of mortal anaphylaxis is as high as 0.8% in bee stings. However, the anaphylactic reactions are not the sole mortal events after bee stings. Kounis syndrome (KS), or allergic myocardial infarctions (MI), are well known concomitant events with every type of allergic reaction. Irrespective of the underlying reasons, KS should be considered in all patients with allergic events and concomitant chest pain symptoms [1,2].

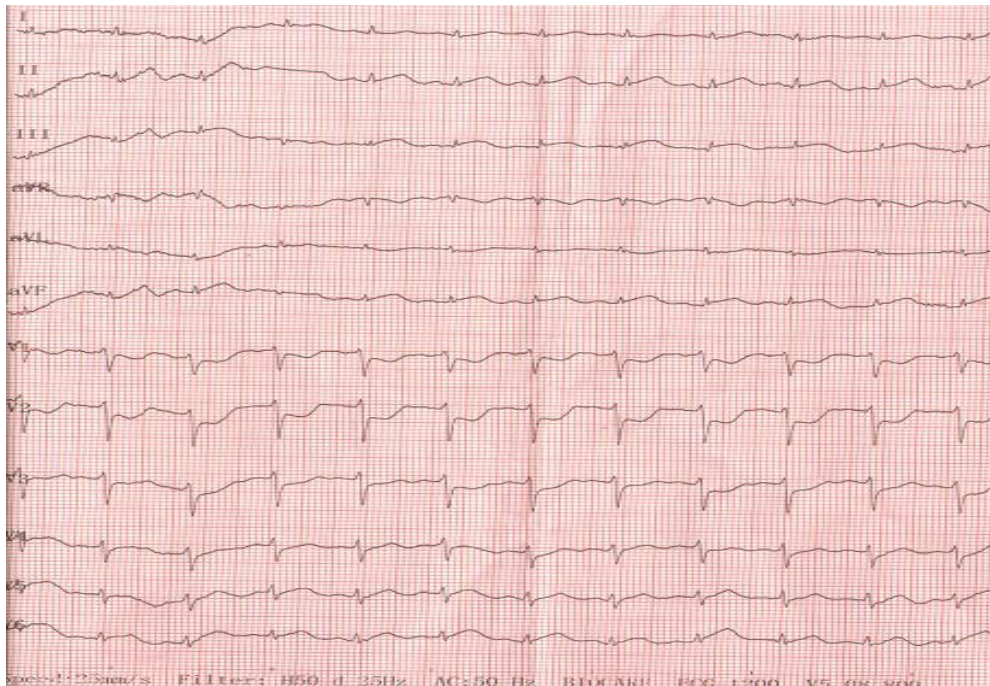
## 2. CASE PRESENTATION

A 46 year old farm worker was brought to the emergency room for allergic symptoms (pruritis) after bee sting. While he had no cutaneous rash, the patient said severe pruritus over his entire body. The patient did not report dyspnea, laryngeal irritation or chest pain. In his history, there was no atopic or chronic disease, and he did not use any drugs. He had been smoking one package of cigarettes a day for about twenty years. He was conscious and communicative. His blood pressure was 160/110 mmHg, his pulse was 110 beat/min and his oxygen saturation was 98%. The appearance of tonsilla, pharynx and uvula was normal, with no pathologic pulmonary sound. While the anti-

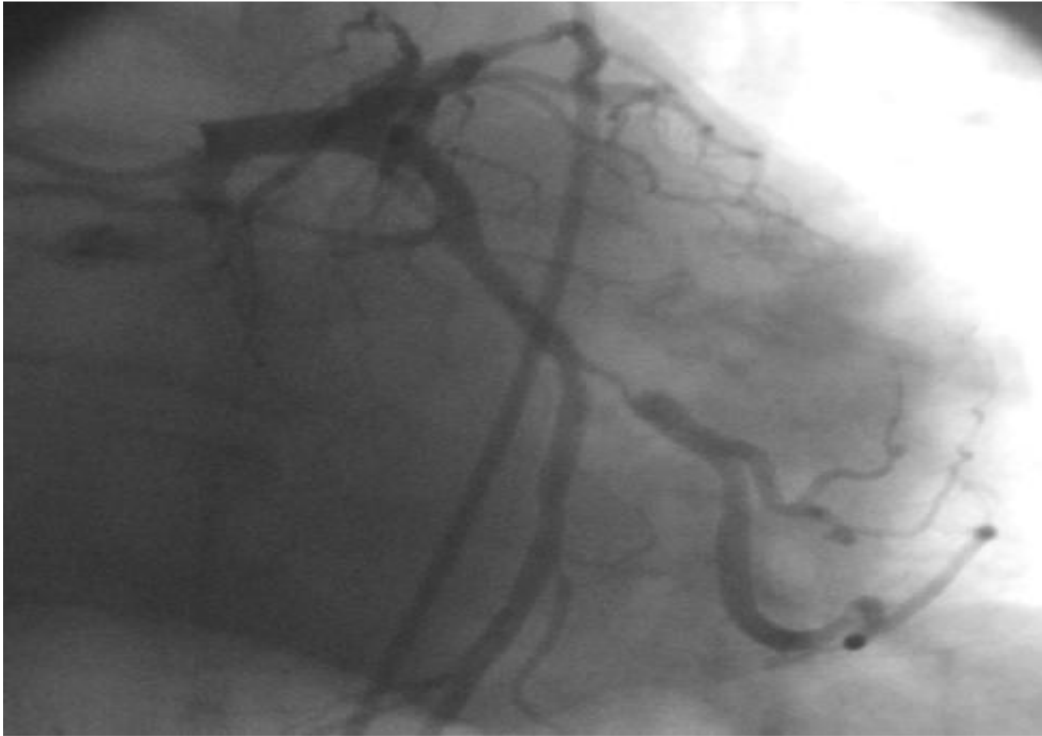
allergic treatment was being initiated, he developed cardiac arrest. He was successfully revived after cardiopulmonary resuscitation. Electrocardiography (ECG) was performed, which revealed minimal ST elevation of D2, D3 and aVF in addition to ST depression for V1,2 (Fig. 1). The patient was given oxygen support and 300 mg of clopidogrel. The percutaneous coronary intervention (PCI) operation also showed a 90% constriction of the circumflex artery (LAD: 50% stenosis, LMCA and RCA: Normal) (Fig. 2). Troponin I levels of the patient, increased (10,36 ng/ml) during follow-up in intensive care unit. He was discharged seven days later.

## 3. DISCUSSION

The term KS involves ACSs that occur soon after anaphylactic reactions. They were firstly defined by Kounis et al. in 1991. KS may be linked to drugs, contrast materials, foods, insect bites, bee stings and latex contacts [2,3]. There are two subgroups of KS, or allergic MI. Type 1 is related to a coronary spasm, which is mediated by histamine, thromboxane and leukotrienes in patients who are lacking any atherosclerotic or coronary artery disease (CAD) history. Type 2 events are seen in CAD patients with the same mediators and are mainly related to



**Fig. 1. Electrocardiography of the patient**



**Fig. 2. Angiography of the patient**

vasospasm, perforation and erosion of intravascular plaques. Recently, a type 3 KS was defined and linked to drug secreting stent implants; thrombus samples were showing eosinophiles and mast cells in these cases [3]. Our patient was a chronic smoker, and he had hypertension (160/110 mmHg) at admission (although no prior history of hypertension was mentioned). Accordingly, he had two risk factors for CAD. The PCI showed evidence of stenosis, so this case fits into the KS type 2 category (i.e., patients with underlying CAD developing MI during allergic events).

Cardiac troponins T, I and C are cardiac regulatory proteins that constitute a complex able to control the calcium-mediated interaction between actin and myosin. Troponin I inhibits the interaction of myosin with actin. In a study by Lippi et al. 31 patients admitted to the emergency department and suffering from anaphylaxis, angioedema and urticaria were found to have significantly increased troponin I serum levels. The authors emphasised the importance of cardiac enzymes to demonstrate potential cardiac injury in patients admitted to the emergency department with acute allergic reactions (especially anaphylaxis) without any

accompanying symptoms of myocardial ischemia [4,5].

When we look at the literature, many allergens (e.g., insect bites, bee stings and drugs) may cause KS among different ages and patient groups. In the literature, there are some case reports, including the following: a 36-year-old woman with clarithromycin use by Bilgin et al. [6], a 14-year-old boy with metronidazole use by Terlemez et al. [7], a 60-year-old diabetic male after a bee sting by Ralpawana et al. [8], a 14-year-old female with oral contraceptives use by Erol et al. [9], and a 43-year-old male with allergic MI after pseudoephedrine use by Celikler et al. [10]. Our patient's KS was observed after a bee sting.

#### **4. CONCLUSION**

In our case, the symptoms of chest pain, dyspnea, syncope and hypotension were lacking. Moreover, conditions such as regular drug use, diabetic disease or neuropathy were also not reported. As a conclusion, we suggest an ECG examination and a cardiac biomarker analysis in all severe allergic cases for detection of KS.

## CONSENT

All authors declare that 'written informed consent was obtained from the patient (or other approved parties) for publication of this case report and accompanying images.

## ETHICAL APPROVAL

It is not applicable.

## COMPETING INTERESTS

Authors have declared that no competing interests exist.

## REFERENCES

1. Sicherer SH, Leung DY. Advances in allergic skin disease, anaphylaxis, and hypersensitivity reactions to foods, drugs, and insect stings. *J Allergy Clin Immunol.* 2004;114:118-24.
2. Kounis NG, Hahalis G, Manola A, Kourelis T, Theoharides TC. Chapter III. Kounis Syndrome (Allergic Myocardial Infarction). In: Galio AP, Jones ML, eds. *Angina pectoris: Etiology, Pathogenesis and Treatment.* Nova Science Publishers, Inc; 2008.
3. Tok D, Özcan F, Şentürk B, Gölbaşı Z. Parenteral penisilin kullanımını takiben gelişen akut koroner sendrom olgusu: Kounis sendromu. *Arch Turk Soc Cardiol.* 2012;40:615-619.
4. Kounis NG, Mazarakis A, Bardousis C, Patsouras N. The heart and coronary arteries as primary target in severe allergic reactions: Cardiac troponins and the Kounis hypersensitivity-associated acute coronary syndrome. *Inter J of Cardio.* 2015;198:83-84.
5. Lippi G, Buonocore R, Schirosa F, Cervellin G. Cardiac troponin I is increased in patients admitted to the emergency department with severe allergic reactions. A case-control study. *Inter J of Cardio.* 2015;194:68-69.
6. Bilgin M, Akyel A, Doğan M, Sunman H, Yeter E. Acute coronary syndrome secondary to clarithromycin: The first case and review of the literature. *Turk Kardiyol Dern Ars.* 2014;42(5):461-3.
7. Terlemez S, Eryılmaz U, Tokgöz Y, Uysal P, Coşan A, Bulut Y. Kounis syndrome caused by metronidazole-A case of 14 year-old boy. *Int J Cardiol.* 2015;20(179):222-4.
8. Ralapanawa DM, Kularatne SA. A case of Kounissyndrome after a hornet sting and literature review. *BMC Res Notes.* 2014;7(1):867.
9. Erol N, Karaagac AT, Kounis NG. Dangerous triplet: Polycystic ovary syndrome, oral contraceptives and Kounis syndrome. *World J Cardiol.* 2014;6(12):1285-9.
10. Celiker M, Tuncer M, Sekeralmaz A. A case with repeated recurrent acute coronary syndrome due to pseudoephedrine use: Kounis syndrome. *Case Rep Med.* 2014;2014:742905.

© 2016 Eroglu et al.; This is an Open Access article distributed under the terms of the Creative Commons Attribution License (<http://creativecommons.org/licenses/by/4.0>), which permits unrestricted use, distribution, and reproduction in any medium, provided the original work is properly cited.

*Peer-review history:*  
*The peer review history for this paper can be accessed here:*  
<http://sciencedomain.org/review-history/12844>