

# A Novel In-built Design to Retain Detachable Cheek Plumpers in Complete Dentures: A Case Report

RACHAPUDI VENKATA ROSHINI<sup>1</sup>, K VAISHALI<sup>2</sup>

## ABSTRACT

Aesthetics is of prime importance to people irrespective of age. Aging and loss of teeth have a significant influence on external facial aesthetics, resulting in sunken cheeks and undesirable facial appearance. Cheek plumper is a prosthesis used to support sunken cheeks, thus enhancing the aesthetics of a person. Hereby, the authors present a case of a 65-year-old male patient, who reported with the complaint of missing upper and lower teeth. Intraoral examination revealed completely edentulous maxillary and mandibular arches. Extraoral examination revealed sunken cheeks. The patient was concerned about his appearance and wanted treatment for it. The treatment plan was to fabricate a complete denture with detachable cheek plumpers. This novel technique offers a simple and effective way to re-establish the lost facial aesthetics. The technique was simple, easy to fabricate and had good patient satisfaction, compared to the other techniques and methods. Follow-up after 24 hours, three months and six months was scheduled and the patient was satisfied with the prosthesis.

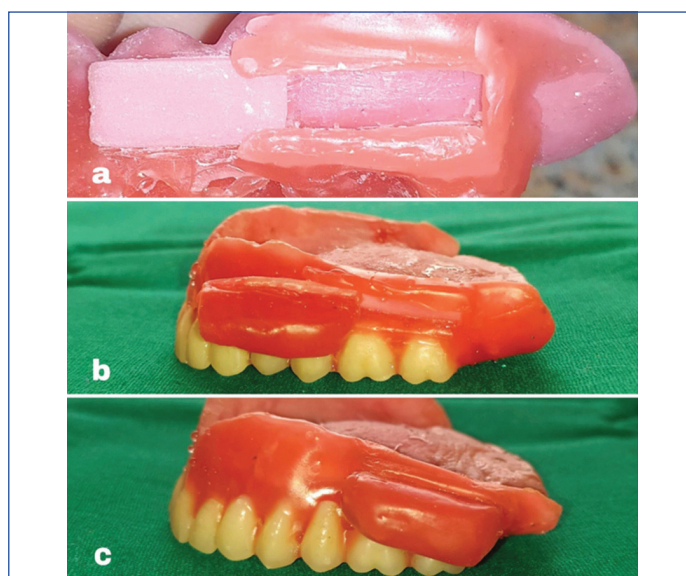
**Keywords:** Irreversible hydrocolloid, Modelling wax, Sunken cheeks

## CASE REPORT

A 65-year-old male patient with a history of broken dentures since a month, reported to the Department of Prosthodontics, Crown and Bridge, for the fabrication of new complete denture prosthesis. The patient presented with no history of medical illness. The patient had been edentulous and was using complete dentures for five years, which fractured a month back. Along with the replacement of teeth, patient desired an improvement of facial appearance, as he presented with sunken cheeks. The proposed treatment was fabrication of complete dentures with detachable cheek plumpers. Informed consent was obtained from the patient and treatment was initiated.

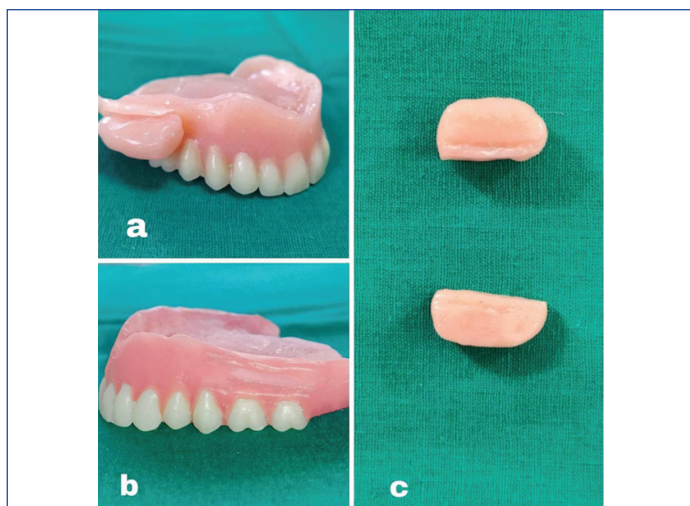
Primary impression of the maxillary and mandibular edentulous arches had been made with irreversible hydrocolloid (Algitec, The Bombay Burmah Trading Corporation, India). Conventional methods of border moulding, secondary impression and jaw relation were followed. Prior to try-in procedure, rectangular templates of dimensions (2.5×1 cm) of 2 mm thickness were fabricated using autopolymerising resin (DPI-RR cold cure, Dental Products of India) [Table/Fig-1a]. These rectangular templates acted as a base, onto which modelling wax was added and shaped in the form of cheek plumpers. To facilitate the sliding in of these rectangular templates, two horizontal slots, corresponding to its length and one vertical slot corresponding to its height at the distal end were made with wax. The slots were positioned 2 mm above the cervical region of acrylic teeth, extending from mesial end of first molar to distal end of second molar on the buccal surface of the maxillary trial denture base. Mesial end of the slot was left open to facilitate the insertion and removal of the cheek plumper [Table/Fig-1b].

The try-in of the denture was carried out in the conventional manner, following which, modelling wax was added onto the resin templates, and placed in the priorly made wax rectangular slots. The contours of the cheek plumpers were assessed based on aesthetic needs of the patient. Once the aesthetics was found satisfactory, the patient was asked to make functional movements like sucking, smiling and pursing of lips and assessed for the retention and stability of the denture during function [Table/Fig-1c]. The waxed-up cheek plumpers were finally finished and polished.



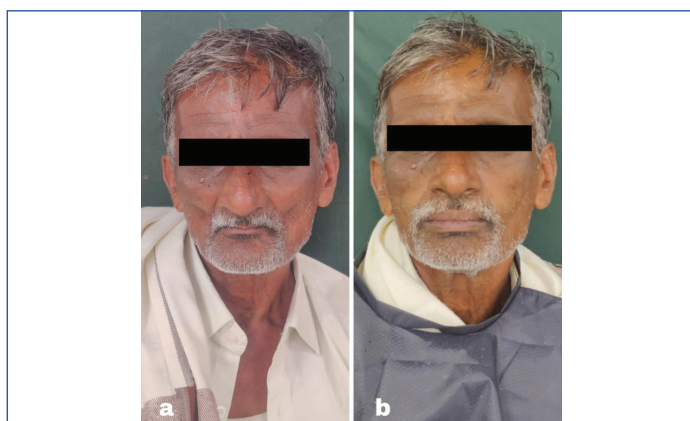**[Table/Fig-1]:** a) Rectangular resin remplate with waxed-up slots for the insertion and removal of cheek plumpers; b) Waxed-up maxillary trial denture along with waxed-up cheek plumpers on the resin templates during insertion in the prepared slots; c) Final waxed-up cheek plumpers positioned in the slots.

The waxed-up dentures and the cheek plumpers were acrylised in separate flasks. Care was taken during the flasking procedure, to accurately reproduce the prepared slots onto the type II Gypsum in the counter flask. The detachable cheek plumpers were invested in a horizontal manner. After dewaxing, heat cure acrylic monomer and polymer (Trevalon HI, Dentsply India Pvt. Ltd., India) were mixed, according to the manufacturers' instructions. During the packing stage, additional care was taken to make sure adequate amount of resin was placed in the region of the slots. Following bench curing for two hours, the dentures and the cheek plumpers were processed at 74°C for two hours and increasing to 100°C for one hour. The dentures were retrieved, trimmed and polished. The cheek plumpers were retrieved, carefully trimmed and checked for the accuracy of fit into the respective slots. Once adequate fit was achieved, the plumpers were polished [Table/Fig-2a,b,c]. In the subsequent appointment, denture insertion was done, as per the required clinical protocol, following which, the cheek plumpers were



**[Table/Fig-2]:** a) Acrylised maxillary denture with detachable cheek plumpers; b) Acrylised maxillary denture with rectangular slot for the insertion and removal of cheek plumpers; c) Acrylised cheek plumpers.

attached and the final aesthetic outcome was evaluated [Table/Fig-3a,b]. Along with the postinsertion denture instructions, the patient was also trained regarding insertion, removal of the denture and cheek plumpers. Patient was educated to give special emphasis on the hygiene maintenance of the denture and the cheek plumpers.



**[Table/Fig-3]:** a) Preoperative view with sunken cheeks; b) Postoperative view with improved aesthetics.

Follow-up was scheduled after 24 hours, three months and six months and checked for denture and cheek plumper retention, occlusion, hygiene and comfort of the patient. At three months follow-up, patient was comfortable with the dentures along with the cheek plumpers, and had no complaints. On clinical examination, there were no signs of muscle fatigue observed. On the assessment of denture, plaque deposits were observed in the slot region of the denture. This was addressed by demonstrating and counselling the patient on good denture hygiene. Patient was comfortable and satisfied with the outcome.

## DISCUSSION

"Beauty matters" it pervades society and affects how we perceive ourselves and others. The desire to look beautiful is not just limited to the young. When patient lose their teeth, they experience loss of chewing efficiency, speech as well as aesthetics. It is the responsibility of the prosthodontist to restore this loss to the best of his/her ability. Cheeks due to the visibility play an important role in facial aesthetics. In a dentulous patient, the form of cheeks is maintained by the underlying musculature, buccal pad of fat along with teeth and their supporting structures. With the loss of posterior teeth, the cheeks tend to collapse in varying degrees and move medially. Further, contour of the cheek is altered due to loss of anterior teeth and vertical dimension. As age advances, there is loss of subcutaneous fat and elasticity of the connective tissues, leading to sunken cheeks [1].

Although conventional complete denture provides soft tissue support in the perioral region, in case of patients exhibiting sunken cheeks, additional support in the form of cheek plumpers is required to restore the facial aesthetics [2]. There is adequate literature available regarding advantage and mode of attachments for detachable cheek plumpers. The present case report throws light on yet another novel way of retaining the cheek plumper in the complete denture. Conventional cheek plumpers were incorporated by increasing the thickness of the distobuccal flange area of the maxillary denture, based on the patients' aesthetic requirement [3]. Their disadvantage is that they increase the weight of the denture, could interfere with masseter muscle and the coronoid process of the mandible and hence, destabilise the maxillary denture, especially during mastication [4,5]. Detachable cheek plumpers are made to reduce the weight of the final prosthesis and improve convenience to the patient. It enables the patient to use the prosthesis without the plumpers, if required [6,7]. It also aids in better maintenance of the prosthesis.

Literature cites various modes of attachment to retain the cheek plumpers. Rewari A et al., Venkatachalapathy SR et al., and Abdelbagi NF et al., reported the use of magnets in conventional complete dentures, single complete dentures and cases with facial disfigurement due to hemimaxillectomy [7-9]. The use of magnet retained plumper prosthesis is effective of all the other methods, but they exhibit poor corrosion resistance and loss of magnetic property over a period of time, requiring frequent replacement. Magnets cannot be used in patients allergic to metal. The patients need to remove dentures for Magnetic Resonance Imaging (MRI) tests since the magnetic field used in MRI tests damages the magnetic assembly. The magnetic assembly should be kept away from high temperatures of more than 150°C [7].

Virdiya NM et al., Kuriakose EM and Swamy RK, and Aggarwal P et al., reported the use of stud attachments as an alternative to magnets [10-12]. Stud attachments provide good retention to cheek plumpers on complete dentures and provide longevity compared to magnets. The limitations of stud attachments are technique sensitivity and chances of breakage over time [11]. Pudi S et al., used die pins and; Patil PP and Madhav VNV, Bharathi BM et al., and Rodrigues MT et al., used customised ball attachments [13-16]. Customised attachments are fabricated in case of space deficiency for the use of readily available attachments, and also for additional retention. The main disadvantage of using the other type of attachments is the presence of metal components, which either corrode or fracture on usage over time.

In the present case report, the fabrication of in-built detachable cheek plumpers in complete dentures has been described, which is economical, does not require any additional materials or equipment, has good aesthetic value, convenient to use for the patient and is non corrosive since, it does not possess any metal component, thus making it advantageous, compared to other techniques.

## Limitation(s)

Limitations of the discussed technique include technique sensitivity, as minor errors during fabrication may lead to misfit of the plumpers. Further, training of the patient with regard to insertion, removal and hygiene maintenance of the plumpers is required.

## CONCLUSION(S)

Cheek plumpers are non invasive treatment modality for restoring the facial aesthetics of patient with sunken cheeks. This paper describes a simple and novel method to fabricate inbuilt detachable cheek plumpers to enhance the aesthetics in such patients. These cheek plumpers are simple to fabricate and are cost effective, without the need of additional metallic retentive aids. Along with enhancing the facial aesthetics, is simple and convenient to use for the patient and also added to the psychological comfort of the patient.

## REFERENCES

- [1] Martone AL. Effects of complete dentures on facial esthetics. *The Journal of Prosthetic Dentistry*. 1964;14(2):231-55.
- [2] Hernández EL, Alvarez A, Abou-Ayash S, Att W. Effect of complete dentures on facial soft tissue volume: A 3D comparative study. *International Journal of Prosthodontics*. 2022;35(2):208-18.
- [3] Raju R, Alani MM, Francis G, Reba PB. A technique to improve complete denture esthetics using cheek plumpers: a case report. *IOSR Journal of Dental and Medical Sciences*. 2020;19(2):52-54.
- [4] Kamakshi V, Anehosur GV, Nadiger RK. Magnet retained cheek plumper to enhance denture esthetics. *The Journal of Indian Prosthodontic Society*. 2013;13:378-81.
- [5] Mor D, Sarapur S, Adeshra K, Pachore N, Rami D. Management of hollow cheeks with undetachable hollow cheek plumper: A case report. *Journal of Advanced Health Sciences and Research*. 2020;1(1):61.
- [6] Keni NN, Aras MA, Chitre V. Customised attachments retained cheek plumper prosthesis: a case report. *The Journal of Indian Prosthodontic Society*. 2012;12(3):198-200.
- [7] Rewari A, Dabas N, Sanan R, Phogat S, Phukela SS, Vigarniya M. Esthetic rehabilitation using magnet-retained cheek plumper prosthesis. *Case Reports in Dentistry*. 2020;2020:2769873.
- [8] Venkatachalapathy SR, Chander GN, Gnanam P. A magnetically retained cheek plumper in a maxillary single complete denture: A clinical report. *Journal of Interdisciplinary Dentistry*. 2019;9(1):25.
- [9] Abdelbagi NF, Ismail IA, Awadalkreem F, Alhaji MN. Detachable lip and cheek plumper for rehabilitation of facial disfigurement. *Case Reports in Dentistry*. 2021;2021:1-6.
- [10] Viridiya NM, Palaskar JN, Wankhade J, Joshi N. Detachable cheek plumpers with different attachments for improving esthetics in a conventional complete denture: A clinical report. *The Journal of Prosthetic Dentistry*. 2017;117(5):592-96.
- [11] Kuriakose EM, Swamy RK. An innovative technique using a plastic button clip retained cheek plumper in complete denture esthetics: a case report. *International Journal of Medical Science and Diagnosis Research*. 2019;3(7):08-11.
- [12] Aggarwal P, Gupta MR, Pawah S, Singh A. An innovative technique to improve complete denture aesthetics using cheek plumper appliance: A case report. *International Journal of Oral Health Medical Research*. 2016;3:51-54.
- [13] Pudi S, Kota S, Ch KK, Kaladi SR, Gade RR. An innovative technique using a stainless steel double die pin retained cheek plumper in complete denture esthetics: a case report. *Cureus*. 2019;11(11):e6197.
- [14] Patil PP, Madhav VNV. Customised ball attachment retained cheek plumpers to enhance facial aesthetics: a case report. *Journal of Clinical & Diagnostic Research*. 2021;15(4):ZD01-ZD03.
- [15] Bharathi BM, Poovani S, Shetty G, Shreya. Complete dentures with detachable cheek plumper-A case report. *International Journal of Scientific Research*. 2019;8(12):44-46.
- [16] Rodrigues MT, Bukkapatnam S, Alva B. Improving facial esthetics with cheek plumpers. *International Journal of Applied Dental Sciences*. 2020;6(4):149-52.

### PARTICULARS OF CONTRIBUTORS:

1. Postgraduate Student, Department of Prosthodontics, Faculty of Dental Sciences, Ramaiah University of Applied Sciences, Bengaluru, Karnataka, India.
2. Reader, Department of Prosthodontics, Faculty of Dental Sciences, Ramaiah University of Applied Sciences, Bengaluru, Karnataka, India.

### NAME, ADDRESS, E-MAIL ID OF THE CORRESPONDING AUTHOR:

Dr. Rachapudi Venkata Roshini,  
Gnanagangothri Campus New Bel Road,  
MSR Nagar-560054, Bengaluru, Karnataka, India.  
E-mail: roshinirachapudi@gmail.com

### PLAGIARISM CHECKING METHODS: [Lain H et al.]

- Plagiarism X-checker: Jan 12, 2023
- Manual Googling: Feb 16, 2023
- iThenticate Software: Mar 21, 2023 (7%)

### ETYMOLOGY: Author Origin

EMENDATIONS: 6

### AUTHOR DECLARATION:

- Financial or Other Competing Interests: None
- Was informed consent obtained from the subjects involved in the study? Yes
- For any images presented appropriate consent has been obtained from the subjects. Yes

Date of Submission: **Jan 05, 2023**

Date of Peer Review: **Feb 10, 2023**

Date of Acceptance: **Mar 29, 2023**

Date of Publishing: **Jun 01, 2023**