



Cemented Bipolar Hemiarthroplasty for Fracture Neck of Femur and Unstable Intertrochanteric Fractures - Prospective and Retrospective Study

P. Sharajdeen ^{a*}

^a *Sree Balaji Medical College & Hospital (Affiliated to Bharath Institute of Higher Education and Research), Chennai, Tamil Nadu, India.*

Author's contribution

The sole author designed, analysed, interpreted and prepared the manuscript.

Article Information

DOI: 10.9734/JPRI/2021/v33i52A33583

Editor(s):

(1) Dr. Giuseppe Murdaca, University of Genoa, Italy.

Reviewers:

(1) K. B. Ravi, Nims University, India.

(2) Vasanth Kumar, Dr. NTR University Of Health Sciences, India.

Complete Peer review History, details of the editor(s), Reviewers and additional Reviewers are available here:

<https://www.sdiarticle5.com/review-history/72176>

Original Research Article

Received 13 September 2021

Accepted 27 November 2021

Published 30 November 2021

ABSTRACT

Hip fractures in elderly patients are becoming a major social problem from various perspectives, including the progressive aging of global societies. The elderly have a high risk of hip fracture, even with minor injuries because of osteoporosis, while early surgical treatment may be difficult due to comorbidities and medication. In this study, significant risk factors were identified. Patients over age 70 had three times the mortality of younger patients. Greater than three pre-existing medical conditions is associated with a 25 percent mortality rate, more than twice that of healthier patients. Surgery performed on the first day of admission and beyond the fifth day was associated with a 34 percent mortality rate. Those patients operated in during days 2 through 5 had a 5.8 percent mortality rate. There was no failures related to inadequate stem or mechanical loosening. The tendency to dislocation can be clinically identifiable by major discrepancy in length, there was no failures related to inadequate stem or mechanical loosening. The tendency to dislocation can be clinically identifiable by major discrepancy in length and only 1 patient had shortening of about 2 cms post operatively which was slightly better than that of James et al (11%).

Keywords: *Mortality; mechanical loosening; dislocation; bipolar; elderly; hemiarthroplasty.*

*Corresponding author: E-mail: shahrukh.f010@gmail.com;

1. INTRODUCTION

Comminuted intertrochanteric fractures with severe displacement are common in elderly patients. These patients have poor bone quality and conventional osteosynthetic procedures frequently lead to non-union and metal failure. The intertrochanteric fractures and femoral neck fractures occur in the more elderly age group. Most inter trochanteric hip fractures can be treated successfully with internal fixation. The failure after internal fixation had been due to initial fracture pattern, comminution, sub optimal fracture fixation and poor bone quality [1-5].

Stable intertrochanteric fractures can be easily managed with osteosynthetic methods with satisfactory results but the same cannot be expected in comminuted and unstable intertrochanteric fractures. Excessive collapse, loss of fixation and cut through of the screw are commonly encountered when conventional osteosynthesis is attempted.

In these patients treatment with primary cemented hemiarthroplasty could perhaps return the patients to their pre injury level of activity more quickly thus obviating the post operative complications caused by immobilization or failure of the implant. The purpose of the present study was to evaluate the results, technical problems with cemented hemi arthroplasty for comminuted, osteoporotic fracture neck of femur and comminuted unstable intertrochanteric fractures of the elderly.

2. METHODOLOGY

This prospective study included 20 cases of elderly patients with mean age of 73.5 years who sustained multifragmentary/communitated intertrochanteric femur fracture treated with Primary cemented bipolar hemiarthroplasty with trochanteric and calcar reconstruction to emphasize the importance of restoration soft tissue tension to reduce the risk of unstable Hemiarthroplasty.

The 30 elderly osteoporotic patients with neck of femur and unstable intertrochanteric fractures were taken for the study. After the preliminary approaches have performed the fracture site is exposed. With the fracture fragments temporarily reduced, the neck of the femur is cut approximately 1 cm above the lesser trochanter. If the fracture in the calcar fragment had extension beyond the lesser

trochanter the fragment was stabilized partially using a cerclage wire or a bone reduction clamp when the femoral canal is reamed. The femoral stem was cemented in place using standard modern cementing techniques that include, lavage, cleaning, drying and plugging of the canal. The fractured greater trochanter with the abductor mechanism was stabilized with the main fragment by using 18 gauge cerclage wire, in a figure of 8 fashion. The wound was closed in layers with a suction drain. The drain was removed at 48 hrs and the patient was made to walk with full weight bearing as tolerated, under the supervision of a physical therapy team.

2.1 Inclusion Criteria

- ✓ Unstable IT fracture (AO 312.2 & 2.3)
- ✓ Patients who are mobile previous to injury
- ✓ No other fracture sustained, only isolated
- ✓ Inter-trochanteric fracture

2.2 Exclusion Criteria

- ❖ Stable IT fractures
- ❖ Age <65yrs
- ❖ Patients unfit for Surgery
- ❖ Patients who were non mobile
- ❖ previous to injury

3. RESULTS AND DISCUSSION

Osteosynthesis of such fractures may reduce the morbidity of pain; it does not permit an early mobilization with a fear of failure of fixation. In old osteoporotic patients surgeon is often confronted with a challenge and dilemma between achieving bony union in a weakened bone stock with poor implants hold, against need for early mobilization. The special problems associated with unstable fractures in the geriatric age group are possibly due to one or more of the following factors: Osteoporosis. Comminution. Age related medical illnesses, and need for rapid mobilization.

Hemiarthroplasty has been used for unstable intertrochanteric fractures since 1971, however less frequently as compared to femoral neck fracture. The outcome of fixation depends mainly on quality of bone, age of patient, general health, trauma surgery interval, adequacy of treatment, comorbidities, and stability of fixation.

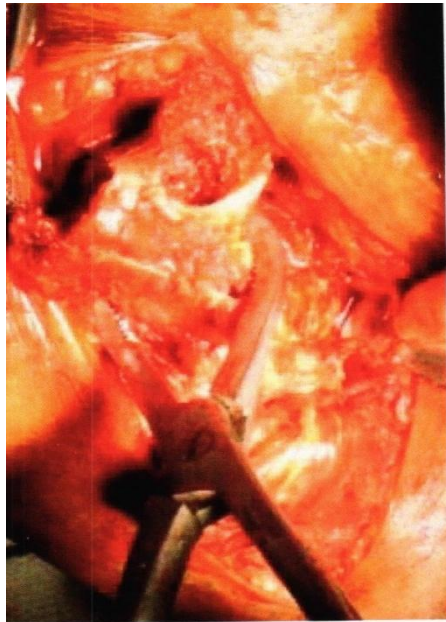
In our study the minimum follow up was 5 months and the maximum follow up was 20 months with a mean follow up of 11.4 months. Maximum number of patients were followed

between 7 to 12 months. Except 2 patients all the other patients had follow up more than 6 months.

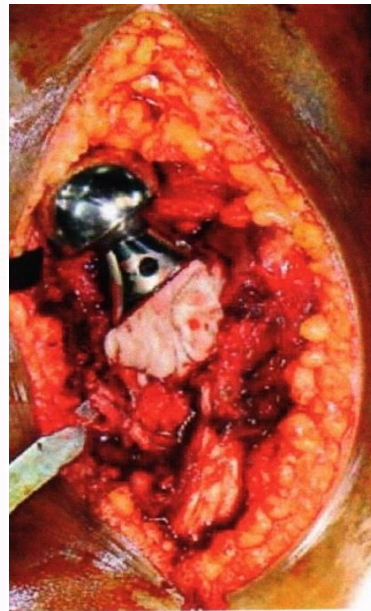The following observations are made in this study: There was a slight female preponderance (56.66%). The incidence of fracture was common in the age group of 71 to 80 years. This shows those elderly age groups were more susceptible. In most of our patients left side (63.33%) was commonly affected. In the distribution of fracture types based on this study 50% were based on neck of femur fractures and other 50% were on intertrochanteric fractures. In majority of our patients the common pre existing

co-morbid conditions are Diabetes mellitus (63.33%), Systemic hypertension (43.33%), Coronary artery disease (20%), Chronic renal failure (3.33%). In most of the patients the Singh's Index was Grade 3 (56.66%).

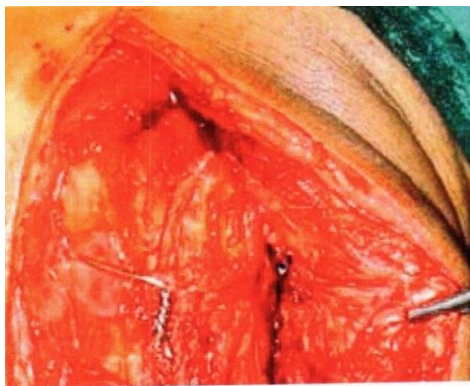Kenzora et al found on overall mortality rate of 15 percent in fractures about the hip compared to an expected mortality rate of 9 percent for the normal population. In his study, significant risk factors were identified. Patients over age 70 had three times the mortality of younger patients. Greater than three pre-existing medical conditions was associated with a 25 percent mortality rate, more than twice that of



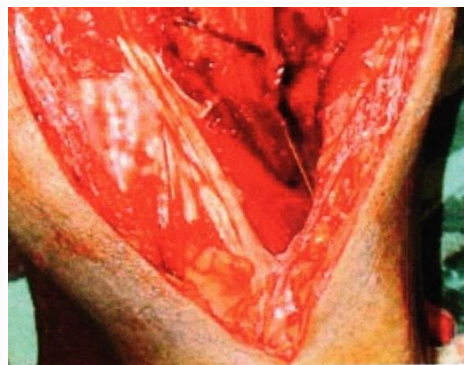
Lateral approach



Temporary Reduction



Prosthesis Insertion



Greater Trochanter Reattachment

Fig. 1. Intra operative picture

healthier patients. Surgery performed on the first day of admission and beyond the fifth day was associated with a 34 percent mortality rate. Those patients operated in during days 2 through 5 had a 5.8 percent mortality rate. In our study with short term analysis (56.66%) were female which compares favourably with that of Stuart et al (75%) which shows definite female preponderance in whom there is an increased prevalence of osteoporosis . The mean age of our patients was (72) years which were lower than that of other studies Stuart et al (82.2 years), Chang et al (84.2 years) . This may be due to shorter life span for Indians when compared to western population. In (63.33%) of our patients left side was involved. This was similar to Mark B Stem et al (left- 58% [6-10]. In our study (96.66%) of patients (29 out of 30 patients who survived) retained walking ability after surgery (82% Chang et al, 76% Laskin et al, 78% Miller et al) Potential long term problems associated with prosthetic replacement such as loosening, acetabular erosion, stem failure, late infection and dislocation may yet occur and it needs a long term follow-up.

4. CONCLUSION

We hereby conclude that primary cemented bipolar hemiarthroplasty is an excellent option in selective unstable fractures like neck of femur and that of trochanter. It is both cost effective and permits early rehabilitation in the elderly with co morbid conditions.

CONSENT

As per international standard or university standard, patients' written consent has been collected and preserved by the authors.

ETHICAL APPROVAL

As per international standard or university standard written ethical approval has been collected and preserved by the authors.

COMPETING INTERESTS

Author has declared that no competing interests exist.

REFERENCES

1. Baker RP, Squires B, Gargan MF, Bannister GC. Total hip arthroplasty and hemiarthroplasty in mobile, independent patients with a displaced intracapsular fracture of femoral neck: a randomized controlled trial JBJS. 2006;88A:2583.
2. Frihagen F, Nordsletten L, Maden JE. Hemiarthroplasty or internal fixation for intracapsular displaced femoral neck fractures. BMJ. 2007;335:1251.
3. Boyd HB, Griffin LL. Classification and treatment of trochanteric fractures. Arch Surg. 1949;58:853.
4. Broos PL, Willemsen PS, Rommens PM, et al. Pertrochanteric fractures in elderly patients: Treatment with a long stem long neck endoprosthesis, Unfallchirurg. 1989; 92:234.
5. Bhandari M, Devereaux PJ, Swiontkowski MF, et al. Internal fixation compared with arthroplasty for displaced fractures of femoral neck. JBJS. 2003;85A:1673.
6. Evans EM. The treatment of trochanteric fractures of the femur. JBJS. 1949;31B(2):190-203.
7. Hopley C, Stengel D, Ekkernkamp A, Wich M. Primary total hip arthroplasty versus hemiarthroplasty for displaced intracapsular hip fractures in older patients. BMJ. 2010;340:C2332.
8. Khan RJ, Mac Dowell A, Crossman P, et al. Cemented or uncemented hemiarthroplasty for displaced intracapsular femoral neck fractures. Int Orthop. 2002;26:229.
9. Chan, K. Casey MD, Gill, Gurudev SMD. Cemented hemiarthroplasties for elderly patients with intertrochanteric fractures; CORR. 2000;371:206-215.
10. Dorr LD. Treatment of hip fractures in elderly and senile patients. Orthop Clin Nor Am. 1981;12:153.

© 2021 Sharajdeen; This is an Open Access article distributed under the terms of the Creative Commons Attribution License (<http://creativecommons.org/licenses/by/4.0>), which permits unrestricted use, distribution, and reproduction in any medium, provided the original work is properly cited.

Peer-review history:
The peer review history for this paper can be accessed here:
<https://www.sdiarticle5.com/review-history/72176>