



Pleural Biopsy in Evaluation of Malignant Pleural Effusion- A Review

**Reshma Babu^{a*#†}, Ulhas Jadhav^{a≡†}, Pankaj Wagh^{a◊†}
and Mona Vohra^{a#†}**

^a Department of Respiratory Medicine, Jawaharlal Nehru Medical College, Datta Meghe Institute of Medical Sciences, Wardha, India.

Authors' contributions

This work was carried out in collaboration among all authors. All authors read and approved the final manuscript.

Article Information

DOI: 10.9734/JPRI/2021/v33i60B34849

Open Peer Review History:

This journal follows the Advanced Open Peer Review policy. Identity of the Reviewers, Editor(s) and additional Reviewers, peer review comments, different versions of the manuscript, comments of the editors, etc are available here: <https://www.sdiarticle5.com/review-history/80272>

Review Article

Received 19 October 2021
Accepted 22 December 2021
Published 25 December 2021

ABSTRACT

Malignant pleural effusion (MPE) is one of the common presentation of many carcinoma including lung, breast and lymphomas. It is very important to make an etiological diagnosis of the MPE cases without any delay as treatment depends on its cause. Cytopathological examination of fluid for malignant cells is the easiest and most sensitive method for detecting malignant pleural effusion (MPE). Despite cytology being a sensitive test, many patients remain undiagnosed, then there is a need of histopathological examination of pleura. Invasive procedures like Closed pleura biopsy (CPB) or thoracoscopy was recommended. CPB was earlier considered an investigation of choice in cases of undiagnosed pleural effusion with good efficacy. Since the emergence of medical thoracoscopy (MT), use of CPB in the diagnosis of cytology negative MPE is gradually declining. However, due to the high cost and challenges associated with the surgery, thoracoscopy is only used in a restricted number of cases. CPB is less reliable than cytopathological testing of fluid or MT in determining MPE. Yet, it is a simple procedure with little procedure-related complication. The purpose of this article is to assess the clinical presentation and approach to MPE, as well as the role of CPB in diagnosing MPE and to investigate the benefits and drawbacks of CPB."

Junior Resident;

≡ Professor and Head of the Department;

◊ Assistant Professor;

† Dr.;

*Corresponding author: E-mail: reshmasbabu19@gmail.com;

Keywords: Malignant pleural effusion; closed pleural biopsy; thoracoscopy.

ABBREVIATIONS

CT : Computed Tomography
MPE : Malignant Pleural Effusion
EPE : Exudative Pleural Effusion
USG : Ultrasonography
CPB : Closed Pleural Biopsy
PE : Pleural Effusion
PET : Positron Emission Tomography
ADA : Adenosine Deaminase.
MT : Medical Thoracoscopy.
TB : Tuberculosis

1. INTRODUCTION

The second commonest root of exudative pleural effusion (EPE) is malignant pleural effusion (MPE) [1]. The occurrence of pleural effusion(PE) is projected to be > 150,000 cases [2]. Carcinoma of lung and breast and lymphoma are some of the most prevalent sources of pleural effusion(PE), but then almost all cancers have been found to generate MPEs [2]. Detached tumor cells in pleural fluid (PF) or demonstration of these cells in pleura collected by 'percutaneous pleural biopsy, thoracoscopy, or thoracotomy' are used to identify an MPE. In difficult-to-diagnose situations, the likelihood of malignant pleural space infiltration should always be considered. The cytology of PF plays a significant role in study of patients with PE [3]. A cytological investigation is suitable not only for cancer diagnosis, but also for identifying the stage of disease and prognosis. Despite considerable efforts, cause of as many as 15% to 20% of all PE remain unknown [4]. History, clinical examination, and PF studies reveal the diagnosis in the majority of patients. When conventional diagnostic methods fail, invasive diagnostic modalities must be used. 'Needle biopsy of the parietal pleura' is one of these techniques. Cause of around half of all misdiagnosed EPE can be identified with closed pleural biopsy (CPB) [5]. CPB is highly indicative for the two commonest causes of EPE -'TB and malignancy' [6].

Even though the first CPB was performed in 1955 with a 'Vim-Silverman needle' [7], since 1958, biopsy has been done with an Abram's pleural biopsy needle since the procedure is simple, harmless, and cheap [8]. Later two different types of needle were invented by Cope and Radja and seldom Tru-cut biopsy needle is used [9–11]. However, when a

diagnostic pleural aspiration is uncertain, medical thoracoscopy (MT) is the procedure of choice in PE [12]. MT, on the other hand, has a few drawbacks. It is an expensive investigation and requires specialist for procedure. Thoracic surgeon is also required as a backup. It is obvious that it cannot be done on a regular basis in a country like India where resource is limited. In the workup of MPE, CPB is less sensitive than PF cytology or MT. It can, however, be done easily and with little risk of complications. Yet, it can be simply done with nominal complication due to procedure. Furthermore, when cytology is negative, CPB can diagnose 7-12 percent of patients with MPE [13]. CPE is frequently recommended in PE where cytology is inconclusive [14].

This article assesses and reviews the clinical presentation, and approach to MPE and role of CPB in evaluation of MPE in set up where thoracoscopy is not available. This article also gives access to CPB and its complications based on different literature.

1.1 Clinical Presentation

MPE can manifest itself in a variety of ways, ranging from asymptomatic to severe respiratory distress. The maximum patients present with dyspnea, which is caused by a change in chest wall/diaphragmatic mechanics. As a result, the size of the PE may not be proportional to the severity of their complaints, making it tough to forecast the physiological consequences. Chest pain, which is more usually dull rather than pleuritic, and a dry cough are other symptoms associated with MPE. When hemoptysis occurs in conjunction with other symptoms, it may indicate endobronchial malignancy or pulmonary thromboembolism. Most MPE patients have a substantial effusion, and a chest exam can reveal a dull note on percussion and reduced breath sounds. Pleural rubs frequently manifest as pleural effusions that gradually reduce in size and vanish as the effusion progresses.

1.2 Imaging Methods

Chest X-Ray: Findings of MPE on Plain chest X-Ray are typical (Fig. 1). Chest X-ray detects PE when there is two hundred millilitre of PF in the Postero-anterior view and fifty millilitre in lateral view' [15]. Pleural effusion is easily recognised in the lateral decubitus view because of shifting of

free pleural fluids between the lower border of the lung and dependent chest wall. In order to check for infiltrates or atelectasis in the underlying lungs lateral decubitus chest radiographs should be done on both sides. The majority of MPE patients present with breathlessness on exertion, and chest X-rays frequently show moderate to large PE (80%), with 10% having massive PE and 10% having less than 500 mL. MPE is likewise characterised by a large, loculated PE and volume loss in the ipsilateral lung.

Ultrasound of the chest: Since it is able to detect even 5ml of PF [16], identifies imaging characteristics indicative of a MPE, and gives image guidance for thoracocentesis and chest tube placement, chest ultrasonography (USG) is being routinely utilised to assess PE cases. As a screening tool, USG is more sensitive in detecting PE than chest X-ray. It aids in determining the pleural thickness and identifying metastasis to pleura. Pleural metastasis usually manifests as ‘small hypoechoic lenticular masses with obtuse margins to the chest wall or as large masses with complex echogenicity’. Thoracic USG can also detect MPE if “it detects pleural thickness (>1 cm), visceral pleural thickening, diaphragmatic thickness (>7 mm) or nodules ,or pleural nodules or irregularities” [17]. There is evidence that pre-procedural USG identifies the suitable site for drainage and septations and thereby reduces the rates of problems due to procedure and has become the part of standard

treatment [18,19]. Post procedure, USG has become a good technique for assessing lung re-expansion following fluid drainage and identifying potential pneumothorax in suspected instances.

CT (Computed Tomography): A CT scan with contrast of the thorax will aid in distinguishing benign from malignant diseases of pleura. To improve diagnostic sensitivity, a CT before therapeutic thoracocentesis is done to for imaging both the parietal and visceral pleurae. The following CT thorax results support MPE:

(1) circumferential and nodular pleural thickening, (2) thickness of parietal pleura larger than one centimetre, and (3) mediastinal pleura infiltration or signs of a primary tumour.” Chest CT identifies tumour infiltration of thoracic structures such as the superior vena cava which aids in the diagnosis of a paraneoplastic effusion.

PET scan: PET scanning, because of its large false positives and limited role in identifying the tumour at the start of disease is not used routinely in separating malignant from benign PE. Fluorodeoxyglucose (FDG) PET imaging is often utilised in the staging of cancers. PET imaging had a moderate sensitivity and specificity for the diagnosis of malignancy (82 percent and 74%, respectively), indicating that PET imaging will probably miss tumour in its early stage and misclassify malignant effusion as inflammatory pleuritis according a recent study [20].

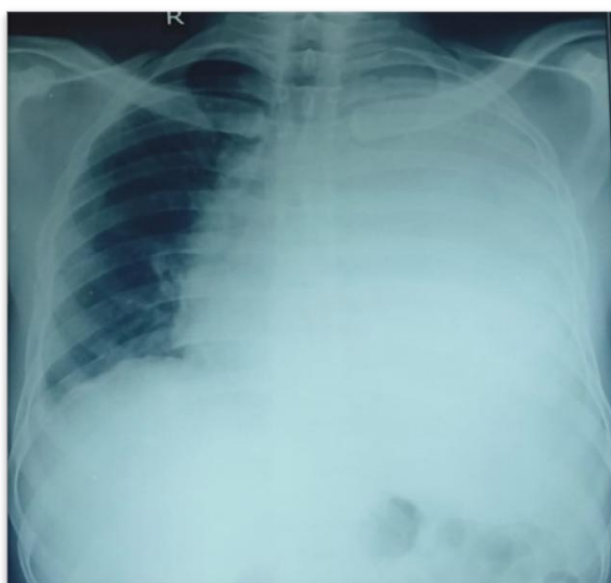


Fig. 1. Chest X-ray PA view showing left sided massive effusion

2. THORACOCENTESIS

Thoracocentesis is commonly used for diagnostic and therapeutic purposes. An USG is done just before the procedure to provide direct guidance and to identify and mark the appropriate entry point. Diagnostic thoracocentesis is done if the fluid thickness on the lateral lying position chest X-ray or the CT scan is < 10 mm. A haemorrhagic diathesis is the main contraindication to a diagnostic thoracocentesis. Recent research has also found that there is no surge in the threat of bleeding with uncorrected coagulopathy or other bleeding risk factor like kidney disorders, antiplatelet drugs use or thrombocytopenia [21]. For exact judgment, a diagnostic fluid aspiration with cytological, microbiological and biochemical examination of the fluid is mandatory.

Therapeutic thoracocentesis can help alleviate dyspnoea generated by a massive pleural effusion. In patients with undiagnosed effusions, removing as little as 300-500 mL at a time is usually enough to alleviate dyspnoea [17]. Therapeutic thoracocentesis should be halted when symptoms such as chest tightness, chest pain, breathlessness, or mild cough occur to avert re-expansion pulmonary oedema. Accompanying illness such as tumour, lymphangitis carcinomatosa, COPD, atelectasis, or pulmonary embolism, need to be investigated if there is no improvement in breathlessness following therapeutic thoracocentesis in malignant effusion [17].

3. GROSS APPEARANCE OF FLUID

The gross appearance of the pleural fluid is commonly utilized as a source of useful diagnostic information. A red coloured fluid suggests presence of blood (malignant illness, pulmonary embolization or trauma), whereas a brownish tinged fluid implies presence of blood over an extended duration of time. A fluid haematocrit (greater than 50% of blood haematocrit) should be measured since the gross bloody pleural fluid suggests haemothorax. *Aspergillus Niger* or *Rhizopus Oryza* infection or metastatic cancer and melanoma associated bleeding cause blackish coloured PE.

4. ANALYSIS OF PLEURAL FLUID

MPE is typically exudative, but 5–10% cases are transudative. The colour and character of the fluid can occasionally help to narrow down the

differential diagnosis. pH, protein, lactate dehydrogenase, and glucose levels, as well as differential cell count and cytopathological examination, are typically determined during routine pleural fluid evaluation (Table 1). The cut off value for transudates and exudates is a total nucleated cell count of 1000/mL. Transudative effusions have a total cell count < 1000/mL, while exudative fluid have higher counts.

Pleural fluid pH is also elevated as a result of the sample being exposed to air (CO₂ escape) and there is a delay of 4 hours or more for the test [22]. Increased acid production by pleural fluid cells and bacteria (e.g., empyema or complicated parapneumonic effusion, oesophageal rupture) or a defective pleural membrane that limits hydrogen ion outflow from the pleural space into the circulatory system (e.g., TB, rheumatoid pleuritis or malignancy) can cause a fall in pH. A poor prognosis is linked to pH value of 7.3 or below in the MPE and the need for an invasive intervention with chest tube drainage. In MPE, a low pH level (less than 7.30) of PF was associated with higher cytology positivity, presumably poorer outcomes, and poor response to chemical pleurodesis when equated to patients with a normal pH of pleural fluid.

Pleural fluid with low sugar (less than 60 mg/dl) seems to have a low pH of 7.20 and high LDH levels overall. Lower glucose of pleural fluid (less than 60 mg/dl) is most commonly caused by a complex malignancy, parapneumonic effusion, rheumatoid pleuritis and tuberculosis although it can also be caused by haemothorax, paragonimiasis, lupus pleuritis and Churg-Strauss syndrome.

Adenosine deaminase (ADA) is an enzyme that is essential for lymphoid cell differentiation. Its activity is high in diseases that stimulate cellular immunity. Although pleural adenosine deaminase activity (ADA) measurement is a useful diagnostic tool for tuberculous pleurisy, false-positive results from non-tuberculous effusions have been reported. It is recommended that the activity of both ADA1 and ADA2 isoenzymes, as well as the 2'-deoxyadenosine/adenosine activity ratio, be estimated in order to improve the diagnostic value of ADA. A study showed that there was no one with ADA level above 40 U/L in the group of patients with MPE [23]. In general, elevated effusions more than 40-45 U/L indicate tuberculosis effusion, although it can also occur in rheumatoid pleuritis or empyema.

Table 1. Pleural fluid findings suggestive of malignant pleural effusion (MPE) [15]

Cell Counts:

Lymphocytes: More than 50% of MPEs have lymphocyte - predominant effusions (lymphocytes = 50%- 70% of nucleated cells).Lymphocyte counts>85% suggest tuberculous pleurisy. lymphoma. sarcoidosis, chronic rheumatoid pleurisy, yellow-nail syndrome. or chylothorax

Erythrocytes: Bloody effusions common with MPE but also found with benign asbestos pleurisy. postcardiac injury syndrome. trauma. and pulmonary infarction

Eosinophils: From 12%-24% of eosinophilic effusions (>10% eosinophils) are malignant in etiology

Protein and LOH Most MPEs are exudates according to Light criteria: 3%-10% are transudates. LOH

>1000 IU/L narrows the differential diagnosis to MPE. empyema. rheumatoid pleurisy. and pleural paragonimiasis

Amylase 1 %-8% of pleural P.ffusions are rich in amylase (>100 IU/L) and so routine amylase measurement is not cost-effective unless pancreatic disease or ruptured oesophagus is strongly suspected before the test. Higher pleural fluid concentrations are associated with shorter survival times among patients with MPE'

pH Levels <7.30 in 30% of MPE cases- :decreasing pleural fluid pH correlates with decreasing survival and success rates with pleurodesis however. in the absence of other clinical information, the correlation does not assist patient selection for pleurodesis

Glucose Levels <60 mg/dL suggest MPE. rheumatoid pleurisy. complicated parapneumonic effusion. tuberculous pleurisy, lupus pleuritis

5. TUMOUR MARKERS

Several tumour markers, including cancer antigen (CA)125, CA15-3, carcinoembryonic antigen (CEA) and CYFRA21-1, have low sensitivity (30%) at cut off levels with high specificity (100%). However, when combined, the sensitivity is comparable to that of pleural fluid cytology (about 50%) [24]. Mesothelin and fibulin-3 levels in pleural fluid have recently been found to be useful in the diagnosis of mesothelioma. However, pleural tumour marker readings cannot be used in place of a definitive cytohistological examination [17].

6. BRONCHOSCOPY

Bronchoscopy may be beneficial for patients with pleural effusions for one or more of the following reasons:1) haemoptysis; 2) pulmonary infiltrates on a chest radiograph or CT scan 3) significant PE encompassing more than three-quarters of the hemithorax; and 4) mediastinum displaced toward the effusion's side which is observed in endobronchial mass lesion. In reviewing his experience with chest malignancies, LeRoux concludes that fiberoptic bronchoscopy, when combined with a pleural effusion as well as another abnormalities on chest radiography, has a diagnostic yield of about 50% [25].

7. CYTOLOGY OF PLEURAL FLUID

Cytology of PF is still the most simple definitive technique of diagnosing malignant effusion and varies depending on tumour severity and tumour type. Cytology has an investigative efficacy of nearly 60% [12], with low sensitivity of 6% for mesothelioma and high sensitivity of 79% for adenocarcinomas [26]. The examination has a poor diagnostic effectiveness because "tumours are not always positioned on the mesothelial cell surface, where tumour cell is exfoliated in PF, but may instead infiltrate the layer underlying the serous layer; consequently, only a little tumour cells will involve the pleural cavity.". In a study, Bhattacharya et al. found that cytopathological examination of three successive samples of PE augmented the diagnosis rate of malignancy [27]. According to one recent study, 10 mL of PF had lesser sensitivity than 60 mL [28].

8. PLEURAL BIOPSY

Cytology of PF has a low investigative yield, and when cytology is inconclusive, pleural biopsy is recommended if MPE is suspected. A piece of the parietal pleura is attained for microbiological or histopathological evaluation with a needle biopsy of the pleura. The most common diseases identified with this technique are TB and malignancy. This can be performed blindly or

image guided. The following needles have been used for CPB: (1) Abrams, with a modified hook method, (2) 'Cope, a buttonhook type with a blunt end' (3) 'Raja needle self-opening stainless steel biopsy flap mounted on the inner tube' and (4) 'Vim-Silvermann' an end-cutting needle. 'Vim-Silvermann' needle is not suggested for routine use because the tip's uncertain position inside chest which leads to less chance of obtaining pleural tissue [29].

The 'Abrams and Cope's needles' are commonly used for biopsy. Cope's needle (Fig. 2) is made up of four distinct components: (a) a large outer cannula with sharp end which is square; (b) a hollow, blunt-ended, hooked biopsy trocar; (c) a hollow-bevelled trocar; and (d) a solid thin obturator or styler. Cope's needle always delivers enough tissue sample since hook is secured in the parietal pleura and the engaged segment cropped off. It also have an extra benefit of a

blunted leading end, which moves the lung away from the hook. In addition, once the tissue sample is extracted, an outer cannula remains in the pleural cavity. Hook may be reinserted via the cannula after single needle insertion of the cannula for several "bites." Another advantage of this needle is that it is well suited for thoracocentesis due to its blunt end. The brittle hook of this needle is its main disadvantage [9].

The Abram's needle (Fig. 3) is made of three components: 'a large outer trocar, an inner cutting cannula, and an inner solid stylet'. The Abrams needle, which is popularly used in Europe, has a sturdy framework and a biting technique that allows for sufficient tissue samples. Drawbacks of this needle include (1) its large size that may cause a sinus tract to leak fluid for long periods of time, (2) a faulty hooking method, and (3) entire device removed with each biopsy attempt.



Fig. 2. Cope's needle



Fig. 3. Abram's needle

In one study, CPB was used to diagnose 49.1 percent of undiagnosed EPE [5]. According to James et al., the diagnostic yield of CPB had been 62.2 percent in cases of all EPE, 76.2 percent in tubercular effusions, and 85.7 percent in MPE [6]. Gouda , Dalati et al. equated the diagnostic efficiency of Abram's and Cope's needle which discovered that Cope needle had an 85 percent sensitivity and Abrams needle had a 57.5 percent sensitivity [30].

The complications of pleural biopsy are the same as those of diagnostic thoracentesis. For two reasons, pneumothorax is more with pleural biopsy than with thoracocentesis. Second, while obtaining the biopsy specimen, the visceral pleura may be unintentionally incised, resulting in a small bronchopleural fistula that can lead to a large pneumothorax. The second most common complication of pleural biopsy is bleeding, which can result in haemothorax. A haemothorax can occur if an intercostal vein or artery is accidentally biopsied. One case of a fistula developing from an intercostal vein to intercostal artery (arteriovenous fistula) after pleural biopsy has been reported [31]. In one study, 4 developed small pneumothorax and 3 experienced pain at the biopsy site following a CPB, and these complications happened after 191 attempts for the first pleural biopsy and 22 attempts for repeat pleural biopsy [32]. In 566 thoracoscopy examinations by Viskum et al complication was found to be 7%–8% [33].

A bleeding diathesis is the main contraindication of a pleural biopsy. The presence of an empyema is another contraindication to needle biopsies because it can lead to the development of a subcutaneous abscess. Patient's not cooperating for procedure and local dermal lesions such as herpes zoster infection or pyoderma are also contraindications.

The combination of fluid examination and pleural biopsy will aid in the identification and histological categorization of the majority of MPE, with around 7-12% of patients remaining undiagnosed [34]. MT is the most effective tool for directly investigating the pleural cavity and detecting their tumours at early phases that are restricted to the visceral pleura. However , roughly ten percent PE remains undiagnosed even after MT [35]. Few chest physicians are competent in thoracoscopy, and it is existing only at a few chosen centres; additionally, the cost is extremely expensive for a normal person in a developing nation like India [36-37] .

9. CONCLUSION

CPB can be used to help diagnose MPE. Even with inconclusive cytology, it can also provide definitive histological diagnosis even though MT is the investigation of choice. CPB could be considered as add-on investigation in the diagnostic assessment of EPE in developing countries with limited medical infrastructures due to its low cost, safety, and ease of availability.

CONSENT

It is not applicable.

ETHICAL APPROVAL

It is not applicable.

COMPETING INTERESTS

Authors have declared that no competing interests exist.

REFERENCES

1. Feller-Kopman DJ, Reddy CB, DeCamp MM, Diekemper RL, Gould MK, Henry T, et al. Management of malignant pleural effusions. An Official ATS/STS/STR Clinical Practice Guideline. *Am J Respir Crit Care Med.* 2018;198(7):839–49.
2. American Thoracic Society. Management of malignant pleural effusions. *Am J Respir Crit Care Med.* 2000;162(5):1987–2001.
3. Soe Z, Shwe WH, Moe S. A study on tuberculous pleural effusion. *International Journal of Collaborative Research on Internal Medicine & Public Health [Internet].* 2010;2(3). [Cited 2021 Oct 28] Available:<https://internalmedicine.imedpub.com/abstract/a-study-on-tuberculous-pleural-effusion-6018.html>
4. Hirsch A, Ruffie P, Nebut M, Bignon J, Chrétien J. Pleural effusion: laboratory tests in 300 cases. *Thorax.* 1979;34(1):106–12.
5. Al-Shimemeri AA, Al-Ghadeer HM, Giridhar HR. Diagnostic yield of closed pleural biopsy in exudative pleural effusion. *Saudi Med J.* 2003;24(3):282–6.
6. James P, Gupta R, Christopher DJ, Balamugesh T. Evaluation of the diagnostic yield and safety of closed pleural biopsy in the diagnosis of pleural

- effusion. *Indian J Tuberc.* 2010;57(1):19–24.
7. DeFrancis N, Klosk E, Albano E. Needle biopsy of the parietal pleura. *New England Journal of Medicine.* 1955;252(22):948–9.
 8. Abrams L. A Pleural-biopsy punch. *The Lancet.* 1958;271(7010):30–1.
 9. Cope C. New pleural biopsy needle: Preliminary study. *Journal of the American Medical Association.* 1958;167(9):1107–8.
 10. Ogirala RG, Agarwal V, Aldrich TK. Raja pleural biopsy needle: A comparison with the abrams needle in experimental pleural effusion. *Am Rev Respir Dis.* 1989;139(4):984–7.
 11. McLeod DT, Ternouth I, Nkanza N. Comparison of the Tru-cut biopsy needle with the Abrams punch for pleural biopsy. *Thorax.* 1989;44(10):794–6.
 12. Hooper C, Lee YCG, Maskell N. Investigation of a unilateral pleural effusion in adults: British Thoracic Society pleural disease guideline 2010. *Thorax.* 2010;65(Suppl 2):ii4–17.
 13. Loddenkemper, Gabler, Mai, Brandt, Preussler. Prospective evaluation of biopsy methods in the diagnosis of malignant pleural effusions: Inpatient comparison between pleural fluid cytology, blind needle biopsy and thoracoscopy. *American Review of Respiratory Disease.* 1983;1(Suppl 4):127.
 14. Villena V, López Encuentra A, Echave-Sustaeta J, Alvarez Martínez C, Martín Escribano P. Prospective study of 1,000 consecutive patients with pleural effusion. Etiology of the effusion and characteristics of the patients. *Arch Bronconeumol.* 2002;38(1):21–6.
 15. Heffner JE, Klein JS. Recent advances in the diagnosis and management of malignant pleural effusions. *Mayo Clinic Proceedings.* 2008;83(2):235–50.
 16. Kocijancic I, Vidmar K, Ivanovi-Herceg Z. Chest sonography versus lateral decubitus radiography in the diagnosis of small pleural effusions. *J Clin Ultrasound.* 2003;31(2):69–74.
 17. Porcel JM, Light RW. Diagnostic approach to pleural effusion in adults. *AFP.* 2006;73(7):1211–20.
 18. Sachdeva A, Shepherd RW, Lee HJ. Thoracentesis and thoracic ultrasound: state of the art in 2013. *Clin Chest Med.* 2013;34(1):1–9.
 19. Barnes TW, Morgenthaler TI, Olson EJ, Hesley GK, Decker PA, Ryu JH. Sonographically guided thoracentesis and rate of pneumothorax. *J Clin Ultrasound.* 2005;33(9):442–6.
 20. Porcel JM, Hernández P, Martínez-Alonso M, Bielsa S, Salud A. Accuracy of fluorodeoxyglucose-PET imaging for differentiating benign from malignant pleural effusions: a meta-analysis. *Chest.* 2015;147(2):502–12.
 21. Zalt MB, Bechara RI, Parks C, Berkowitz DM. Effect of routine clopidogrel use on bleeding complications after ultrasound-guided thoracentesis. *J Bronchology Interv Pulmonol.* 2012; 19(4):284–7.
 22. Mishra EK, Rahman NM. Factors influencing the measurement of pleural fluid pH. *Curr Opin Pulm Med.* 2009;15(4):353–7.
 23. Safianowska A, Krenke R, Dmowska-Sobstyl B, Bogacka-Zatorska E, Domagała-Kulawik J, Chazan R. [Adenosine deaminase activity in tuberculous and malignant pleural effusions]. *Pneumonol Alergol Pol.* 2006; 74(1):5–9.
 24. Porcel JM, Vives M, Esquerda A, Salud A, Pérez B, Rodríguez-Panadero F. Use of a panel of tumor markers (carcinoembryonic antigen, cancer antigen 125, carbohydrate antigen 15-3, and cytokeratin 19 fragments) in pleural fluid for the differential diagnosis of benign and malignant effusions. *Chest.* 2004;126(6):1757–63.
 25. LeRoux BT. Bronchial carcinoma with pleural effusion. *S Afr Med J.* 1968; 42:865–866.
 26. Arnold DT, Fonseka DD, Perry S, Morley A, Harvey JE, Medford A, et al. Investigating unilateral pleural effusions: the role of cytology. *European Respiratory Journal [Internet].* 2018;52(5). [Cited 2021 Oct 31] Available: <https://erj.ersjournals.com/content/52/5/1801254>
 27. Bhattacharya S, Bairagya TD, Das A, Mandal A, Das SK. Closed pleural biopsy is still useful in the evaluation of malignant pleural effusion. *J Lab Physicians.* 2012;4(1):35–8.
 28. Swiderek J, Morcos S, Donthireddy V, Surapaneni R, Jackson-Thompson V, Schultz L, et al. Prospective study to determine the volume of pleural fluid

- required to diagnose malignancy. *Chest*. 2010;137(1):68–73.
29. Kettel LJ, Cugell DW. Pleural Biopsy. *JAMA*. 1967;200(4):317–20.
 30. Gouda AM, Dalati TA, Al-Shareef NS. A comparison between Cope and Abrams needle in the diagnosis of pleural effusion. *Annals of Thoracic Medicine*. 2006;1(1): 12.
 31. Lai JH, Yan HC, Kao SJ, Lee SC, Shen CY. Intercostal arteriovenous fistula due to pleural biopsy. *Thorax*. 1990;45(12):976–8.
 32. Rajawat GS, Batra S, Takhar RP, Rathi L, Bhandari C, Gupta ML. Diagnostic yield and safety of closed needle pleural biopsy in exudative pleural effusion. *Avicenna J Med*. 2017;7(3):121–4.
 33. Viskum K, Enk B. Complications of thoracoscopy. *Poumon Coeur*. 1981;37(1):25–8.
 34. Prakash UB, Reiman HM. Comparison of needle biopsy with cytologic analysis for the evaluation of pleural effusion: analysis of 414 cases. *Mayo Clin Proc*. 1985;60(3):158–64.
 35. Cantó A, Blasco E, Casillas M, Zarza AG, Padilla J, Pastor J, et al. Thoracoscopy in the diagnosis of pleural effusion. *Thorax*. 1977;32(5):550–4.
 36. Wernecke K, Vassallo P, Hoffmann G, Peters PE, Poetter R, Rummeny E, Koch P. Value of sonography in monitoring the therapeutic response of mediastinal lymphoma: comparison with chest radiography and CT. *AJR. American journal of roentgenology*. 1991;156(2):265-72. Jain J, Jadhao P, Banait S, Salunkhe P. Diagnostic accuracy of GeneXpert MTB/RIF assay for detection of tubercular pleural effusion. *PLOS ONE*. 2021; 16(6).
 37. Abhilasha SP, Meshram R, Taksande A. Tuberculous Pericardial Effusion in an Infant: A Case Report. *Journal of Evolution of Medical and Dental Sciences*. 2020;9(43):3256-8. Available: <https://doi.org/10.14260/jemds/2020/714>.

© 2021 Babu et al.; This is an Open Access article distributed under the terms of the Creative Commons Attribution License (<http://creativecommons.org/licenses/by/4.0>), which permits unrestricted use, distribution, and reproduction in any medium, provided the original work is properly cited.

Peer-review history:

The peer review history for this paper can be accessed here:
<https://www.sdiarticle5.com/review-history/80272>