



Laparoscopic Fundoplication for Gastro-esophageal Reflux Disease and Hiatus Hernia: A Short Term Outcome of First 8 Cases

**Mushtaq Chalkoo^{1*}, Zahid Mohd Rather², Ferkhand Mohiuddin¹,
Aabid Rasool Bhat¹, Imtiyaz Ahmad Ganie¹ and Syed Shakeeb Arsalan¹**

¹Government Medical College, Srinagar, India.

²Government Medical College, Anantnag, Kashmir, India.

Authors' contributions

This work was carried out in collaboration among all authors. All authors read and approved the final manuscript.

Article Information

DOI: 10.9734/JAMMR/2019/v30i230170

Editor(s):

(1) Dr. Salomone Di Saverio Emergency Surgery Unit, Department of General and Transplant Surgery, S. Orsola Malpighi University Hospital, Bologna, Italy.

Reviewers:

(1) P. K. Hota, Kaloji Narayana Rao University of Health Sciences, India.

(2) Ramesh Kumar, SVS Medical College, India.

(3) Ashrarur Rahman Mitul, Dhaka Shishu (Children) Hospital and Bangladesh Institute of Child Health, Bangladesh.

Complete Peer review History: <http://www.sdiarticle3.com/review-history/49996>

Original Research Article

Received 25 April 2019

Accepted 03 July 2019

Published 15 July 2019

ABSTRACT

Background: Acute gastro-esophageal reflux disease is a common ailment in kashmiri population. Most of these patients are managed by gastroenterologist, physicians and surgeons in daily outpatient basis. Majority of them settle by medical management with the help of proton pump inhibitors, prokinetics and antacids., laparoscopic Nissen's fundoplication (LNF) is currently the procedure of choice for the surgical management of GERD.

Aims and Objectives: The aim of this study was to know the feasibility of laparoscopic fundoplication for hiatus hernia and acute gastro-esophageal reflux disease in terms of operative time, post operative pain, length of hospital stay, conversion rate and recurrence of symptoms.

Materials and Methods: The present prospective observational study was conducted in the Post-Graduate Department of General Surgery and minimal access surgery Government Medical College Srinagar from June 2013 to June 2017. The patients that were included in the study had symptomatic gastro-esophageal reflux (documented by endoscopy) with either persistent

*Corresponding author: E-mail: mushtaq_chalkoo@rediffmail.com;

symptoms despite adequate and prolonged medical treatment, CT documented hiatus hernia and patients, who wanted to avoid long-term medical treatment. The duration of reflux symptoms ranged from 9 months to 30 years (median 6 years). Patients who were excluded from the study were those unfit for anesthesia. Informed consent was taken before surgery in the language, the patients understood.

Results: This study includes 8 patients, with median age of 40 years (range 20-70 years). In the study group, 5 were males and 3 were females. The mean operative time was 90 minutes (range 60 to 120 minutes). There were no major intra operative and post operative complications. The post operative pain was minimal as compared to open surgery. The median hospital stay was 3.5 days (range 3 -6 days). Two patients developed symptoms of bloating, early satiety, nausea and diarrhea. However these symptoms improved within weeks with a good response to appropriate medication. The median time until normal physical activity resumed was 2 weeks (range 3 days to 4 weeks). Median follow-up was 6 months (range 1-12 months). The overall short-term results in appropriately selected patients were excellent. The recurrence of symptoms was not observed in any patient within follow up of 6 months.

Conclusion: We conclude from our early series of 8 cases, that patients having long standing GERD not responding to medical management who are at a threat to develop barrettes esophagus should be given the benefit of laparoscopic fundoplication. However proper evaluation, patient selection is mandatory. The choice of fundoplication should be dictated by the surgeon's preference and experience. Currently, the main indication for laparoscopic fundoplication is represented by PPI-refractory GERD, provided that objective evidence of reflux as the cause of ongoing symptoms has been obtained by impedance-pH monitoring.

Keywords: Laparoscopy; hiatus hernia; reflux; fundoplication.

1. INTRODUCTION

Gastroesophageal reflux disease (GERD) is currently defined as a condition that develops when the reflux of gastric contents into the esophagus leads to troublesome symptoms and/or complications [1,4]. The management of GERD is multi-disciplinary, often involving general practitioners, gastroenterologists, surgeons and specialist nurses, all of whom should have an awareness of the pros and cons of each management option. Barrett's esophagus is a condition in which the stratified squamous esophageal epithelium is replaced by endoscopically detectable columnar metaplasia [5,6]. It occurs in 2% of the general adult population and represents the most dreaded complication of GERD, because it predisposes to esophageal adenocarcinoma, the fastest growing cause of cancer mortality. There is still debate about the working definition of Barrett's esophagus [5,6]. According to the American Gastroenterological Association, Barrett's esophagus is a change in the distal esophageal epithelium of any length that can be recognized as columnar type mucosa at endoscopy and is confirmed to have intestinal metaplasia by biopsy of the tubular esophagus [5]. According to the British Society of Gastroenterology, only 1 cm or more of endoscopically visible columnar epithelium above the gastro-esophageal junction

dictates biopsy sampling, whereas the detection of intestinal metaplasia is not a prerequisite for the definition of Barrett's esophagus but only for the necessity of endoscopic surveillance [6].

Although multiple variants of anti-reflux operations are described, laparoscopic Nissen's fundoplication (LNF) is currently the procedure of choice for the surgical management of GERD. This is reiterated in the RCSE (Royal college of surgeons) guidance, which recommends fundoplication for the surgical management of GERD. Since fundoplication was reported by Nissen in 1956 [7,8], it has become the most common surgical procedure for gastro-esophageal reflux disease, achieving long-term relief of reflux symptoms in 90% of patients [9-11], with low morbidity rates (12-13%) and negligible mortality [12], to reduce the incidence of post-fundoplication sequelae. The fundoplication offers the potential of reduced postoperative pain and hence a shorter stay in hospital and reduced convalescent times compared with the open approach.

1.1 Aims and Objectives

The aim of this study was to know the feasibility of laparoscopic fundoplication for hiatus hernia and acute gastroesophageal disease in terms of operative time, post operative pain, length of

hospital stay, conversion rate and recurrence of symptoms.

2. MATERIALS AND METHODS

The present prospective observational study was conducted in the Post-Graduate Department of General Surgery and minimal access surgery, Government Medical College Srinagar from June 2013 to June 2017. The patients that were included in the study were symptomatic gastro-esophageal reflux (documented by endoscopy) with either persistent symptoms despite adequate and prolonged medical treatment, CT documented and patients, who wanted to avoid long-term medical treatment. The patients who were excluded from the study were those unfit for anesthesia. The following data was collected prospectively: age, sex, operative time, intra-operative and post operative complications, postoperative pain, hospital stay, conversion to open and recurrence of symptoms. All the patients enrolled for the study were evaluated by detailed history, thorough general physical examination, and focused systemic examination. Informed consent was taken before surgery in the language, the patients understood. The patient was kept fasting overnight. All patients received a prophylactic dose of injection ceftriaxone 1 g one hour before surgery.

2.1 Operative Procedure

2.1.1 Position of patient

After induction of general anesthesia and introduction of a bladder catheter, the patient was placed in lithotomy, position, the table tilted 30° head up, and the surgeon standing between the patient's legs with the first assistant to the patient's left and the second assistant to the patient's right. We preferred camera man to stand on the left side of surgeon. We use only one monitor on the side of the right shoulder of the patient. All procedures were completed by using 30 degree telescope

2.1.2 Port position

After placing an orogastric tube to deflate the stomach, Pneumo-peritoneum up to 15 mmHg was achieved by a direct trocar technique. Five ports were used (Fig. 1). A 10 mm optical port for the laparoscope was introduced just to the left of the midline, midway from the xiphisternum to the umbilicus. Additional ports were placed under vision; 5 mm ports was placed in the mid-clavicular line just below the right costal margin

for a fan shaped retractor used for liver retraction, two working ports were made on either side of the optical port, 10 mm working port in the mid-clavicular line 5 cm away from the optical port on the left side of the abdomen, while as 5 mm working port was placed on the right side of abdomen, 5 cm away from the optical port in the mid-clavicular line and additional 5mm port was made in the anterior axillary line for retraction of the stomach by the left assistant

2.1.3 Surgical procedure

Two of the assistants stand on the patient's right side; The camera man and the assistant who retracts the liver. The assistant on the right side of the surgeon pulls the stomach down to expose the gastro-esophageal junction. The first step is to incise the lesser omentum and pars flaccida and proceed up towards the right side of gastro-esophageal junction. The phreno-esophageal membrane is incised and the dissection is carried across the esophagus. The lesser omentum is incised to expose the right crus of diaphragm. A plane is created between the right crus and Para-esophageal tissue and deepened. The Para-esophageal fat is dissected from the esophagus taking care not to damage the hepatic branches of vagus nerve, next to that dissection of esophagus hiatus is done. The dissection of the hiatus is done to mobilize the lower esophagus and making it free from all the structures. The dissection is also carried to the left of the esophagus interiorly till the left crus is reached. A cleavage is developed between the esophageal Wall and the left crus. Again the left Para-esophageal fat is dissected off the esophagus to expose the whole of left crus. Next step is to complete the dissection of esophagus within the the esophageal hiatus and to further extend the peri-esophageal dissection in the mediastinum in order to mobilise enough length of it, thereby avoiding the upward retraction of gastro-esophageal junction and fundoplication. At least 3- 4 cm tension free abdominal esophagus must be present within the abdomen at the end of dissection. During the upper dissection of the hiatus, a great care is taken not to damage the anterior vagus nerve. The mobilization of upper part of the fundus of the stomach is the next step; this is achieved by dividing the gastro esophageal adhesions and short gastric vessels until the upper part of fundus is liberated. The dissection and division of these vessels is greatly facilitated by using harmonic scalpel. After the dissection is completed, the reconstruction beginning by approximately the two pillars in

order to narrow the esophageal hiatus. The narrowing of the esophageal hiatus should be calibrated to a size that allows the supple passage of a 10 mm scope along side of esophagus. The fundus is passed behind the esophagus to initiate the fundoplication. The fundoplication is performed by stitching the both sides of gastric fundus together in front of esophagus. To asses the tightness of gastric wrap, a 5 mm grasper forcepis passed between fundal gastric wrap along side of gastro-esophagus. Anchoring the fundoplication to the esophagus using an additional suture completes the procedure. We also fixed the wrap with the right crus of diaphragm to avoid the prolapse of fundal wrap. The drain was placed and secured in all cases. The ports were closed and dressing applied. (Figs. 1-14).

2.1.4 Postoperative care

To avoid forceful vomiting the first hours postoperatively as this may cause early disruption of the sutures and intra-thoracic migration of the fundoplication an anti-emetics was administered. A naso-gastric tube was routinely kept in place for 24 h after the surgery. Oral fluid intake was started on the 1st postoperative day and soft solids on the 2nd day. Patients left hospital as soon as they are well enough, continuing with a soft diet for the next 4 weeks. All patients were again seen at the outpatient clinic at 1 week, 6 weeks and 6 month after the procedure. Further follow-up was arranged on individual basis.

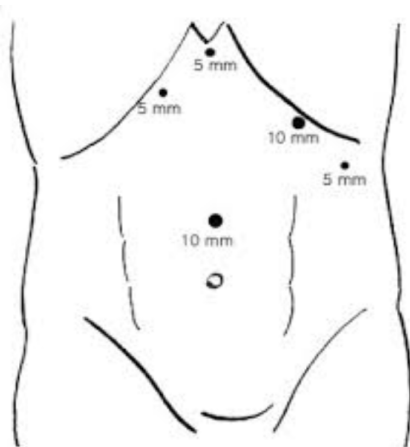


Fig. 1. Port position

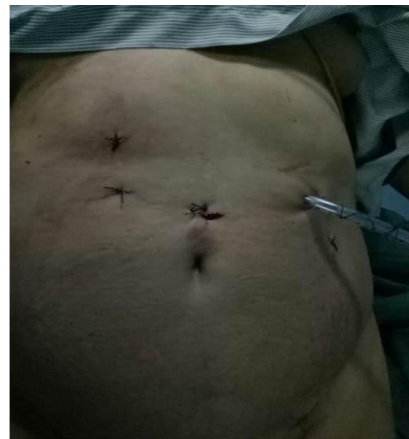

Fig. 2. Post operative picture fundoplication

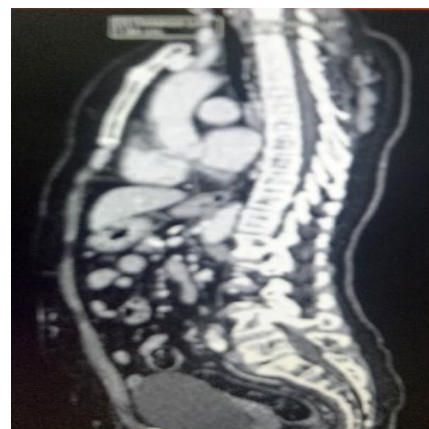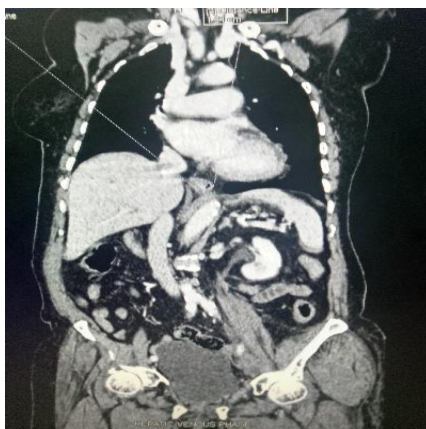


Fig. 3. Longitudinal section of CECT abdomen showing hiatus hernia

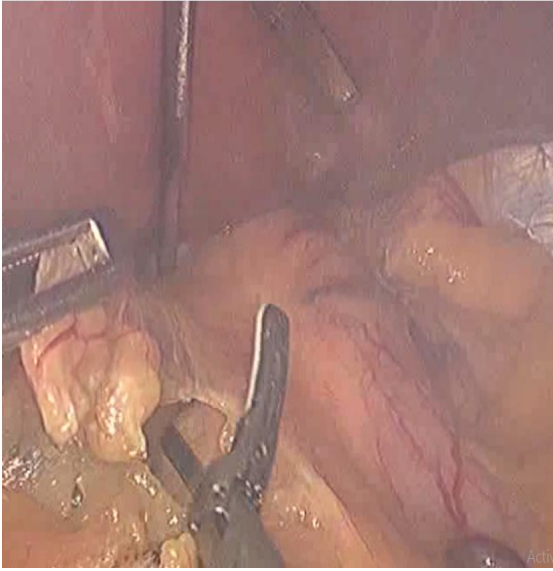

Fig. 4. Release of gastro hepatic ligament by Harmonic. This exposes the lesser sac distally and proximally from the hepatic branches of the vagal nerves which are left intact

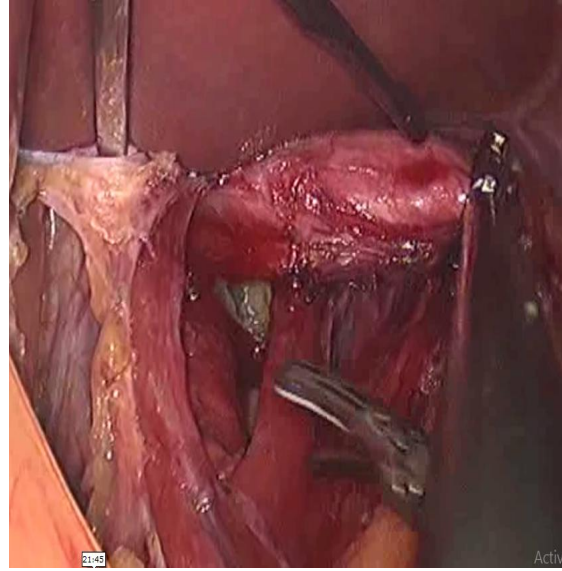


Fig. 5. The right crus is incised and the dissection is extended anteriorly, posteriorly on to the V- shaped commissure of the right crus. The mediastinum is opened widely which helps in localizing the left pillar and esophagus

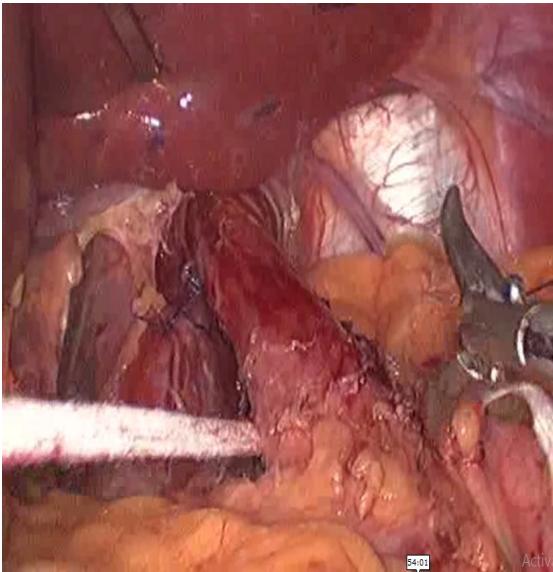


Fig. 6. A ribbon gauze is passed in the window behind the esophagus and placed around the abdominal part of esophagus. This maneuver allows the traction onto the esophagus and gastroesophageal junction which helps in opening dissection planes

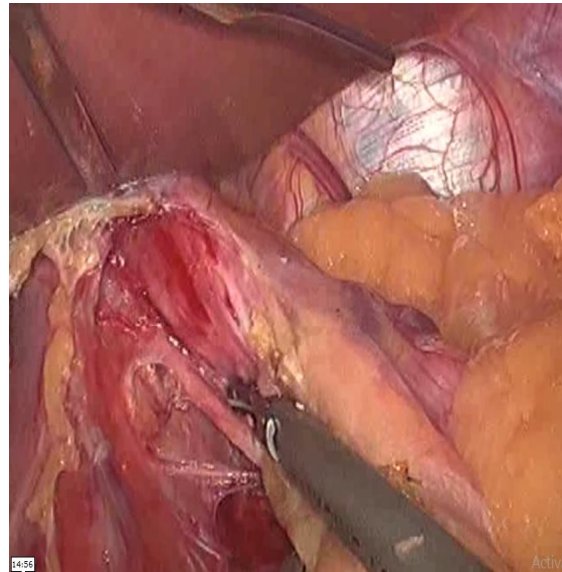


Fig. 7. Vagus nerve on the posterior aspect of esophagus. Continuously keeping in mind the presence of both vagus nerves limits the possibility of harming them

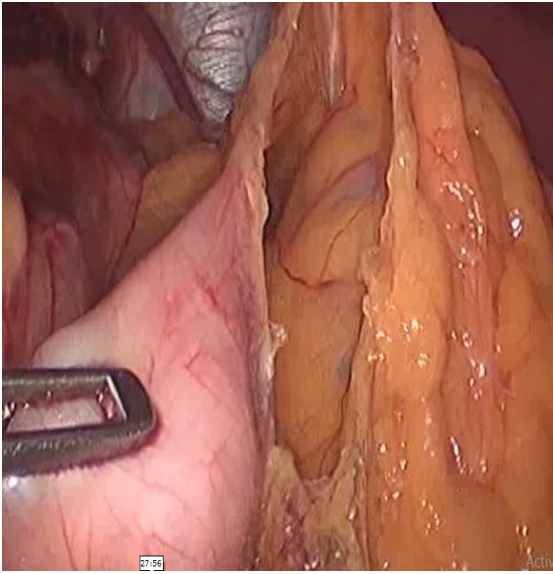


Fig. 8. The greater omentum is dissected from the stomach along the greater curvature. The short gastric vessels are divided individually using the harmonic scalpel. It is important to mobilize the fundus completely away from the diaphragm i.e until reaching the base of the pillar posteriorly to avoid undue torsion on the gastro esophageal junction when constructing the fundoplication

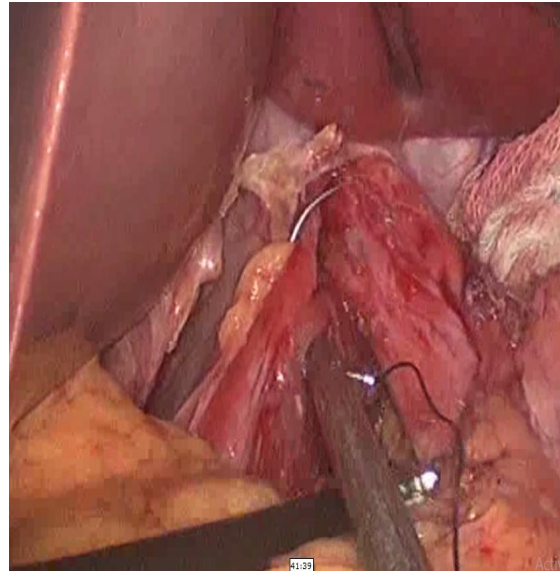


Fig. 9. The pillars are approximated from the right of the esophagus with interrupted nonabsorbable sutures. In order to narrow the opening of esophageal hiatus

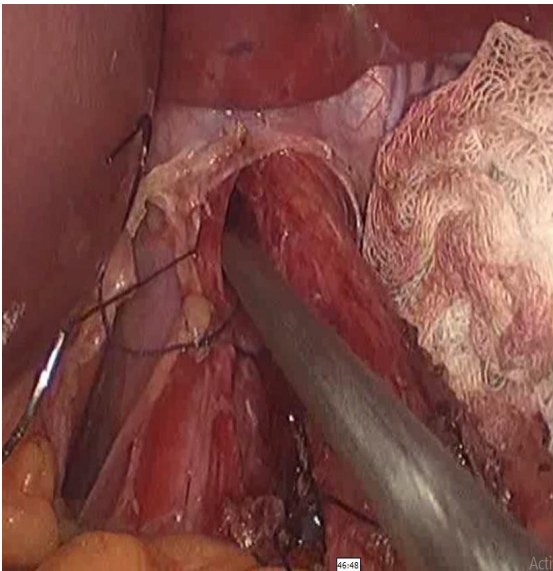


Fig. 10. Narrowing of esophageal hiatus is assessed by passing grasper forcep alongside of esophagus

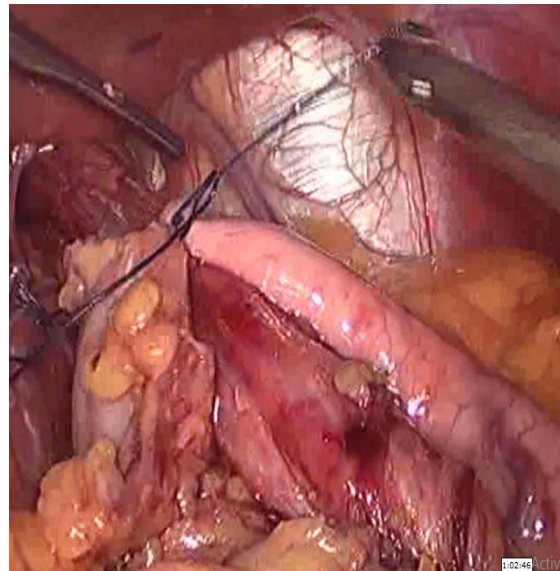


Fig. 11. The fundoplication is performed by stitching both sides of gastric fundus together in front of esophagus

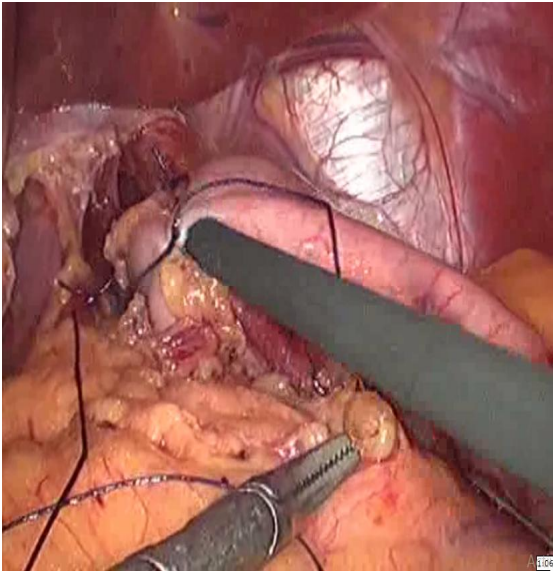


Fig. 12. To access the tightness of gastric wrap Grasper forcep is passed between fundal gastric wrap and esophagus

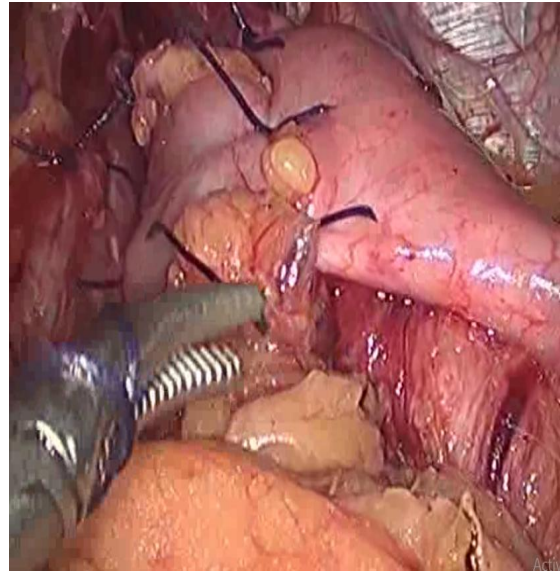


Fig. 13. Complete fundoplication

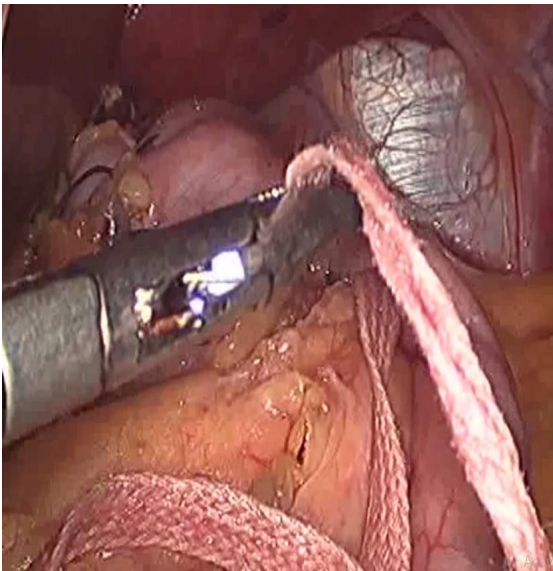


Fig. 14. Removing the ribbon gauze. The Floppy aspect of the fundoplication is again Checked by passing grasper alongside of esophagus

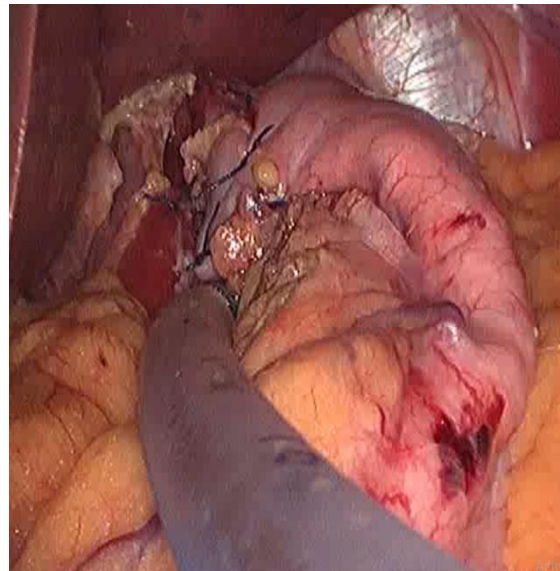


Fig. 15. Drain placed and secured

3. RESULTS

This study includes 8 patients, with median age of 40 years (range 20-70 years). In the study group 5 were males and 3 were females. The mean operative time was 90 minutes (range 60 to 120 minutes). There was no major intra

operative and post operative complications (such as bleeding, perforation of esophagus, injury to diaphragm, phrenic nerves and conversion to open). The post operative pain was minimal as compared to open surgery. The median hospital stay was 3.5 days (range 3 -6 days). Two patients developed symptoms of bloating, early

satiety, nausea and diarrhea. However these symptoms improved within weeks with a good response to appropriate medication. The median time until normal physical activity was resumed was 2 weeks (range 3 days to 4 weeks). Median follow-up was 6 months (range 1-12 months). All patients were currently free of reflux symptoms. Postoperative gastroscopy was performed in all patients, revealing a satisfactory fundoplication on direct inspection and the absence of oesophagitis in all patients. The overall short-term results in appropriately selected patients were excellent. The recurrence of symptoms was not observed in any patient within follow up of 6 months.

4. DISCUSSION

Acute gastro-esophageal reflux disease is a common ailment in Kashmiri population. Most of these patients are managed by gastroenterologist, physicians and surgeons in daily outpatient basis. Majority of them settle by medical management with the help of proton pump inhibitors, prokinetics and antacids [1,2,3]. There is an association of gall stones with esophageal reflux disease and duodenum diverticulum (saint's triad). Gastro-esophageal reflux disease and gall stone presentation share the common clinical scenario of symptoms. It is difficult to differentiate the one entity from the other clinically. Unfortunately, there are only few places in our state, where these patients would be evaluated in the true scientific spirit and helped on scientific logical ground. Under this perspective most of these patients stay on a continued medical management of PPIs even though they could be helped by surgical management called Nissen's fundoplication. To detect acute gastro-esophageal disease, we need impedance PH monitoring, esophageal manometry and establish imaging diagnosis of hiatus hernia, we require endoscopy and CECT scan. The patients that were sent to us were highly suspicious of having acute gastro-esophageal disease on clinical scoring systems and having a resistance to treatment by PPIs for duration of more than two years. The patients having acute gastro-esophageal disease were with the persistent symptoms of retrosternal burning pain, regurgitation of gastric aspirate, hoarseness of voice and irritative cough [13,14]. The patients with hiatus hernia were Nissen's fundoplication were performed were diagnosed on clinical, radiological (barium meal study), Endoscopy and CECT scan. Stein and De-

Meester [15] have stated that the established principles of anti-reflux surgery should not be jettisoned in order to perform a procedure laparoscopically. They state that the 'construction of a loose 360° fundoplication' should be the goal. Dallemagne et al. [16] demonstrated the feasibility of this in their initial series of 12 patients. Geagea [17] and Falk et al. [18] all reported good initial results in preliminary series of 10 and 16 patients, respectively. Five patients of our study group presented with a documented hiatus hernia on endoscopy and CT scan. Four of them had sliding hiatus hernia and one had Para-esophageal type. However the rest three patients were taken for surgery for acute gastro-esophageal disease on their clinical presentation only, due to paucity of esophageal manometry and PH monitoring. We could not document their reflux before taking them for surgery. Nevertheless, after a threadbare discussion with the treating gastroenterologist, a unanimous consensus was generated that Nissen's fundoplication will help these patients. It is agreed that the two entities may coexist together, however it is also known that they are not related to each other. A small hiatus hernia may have severe symptoms of gastro-esophageal disease and converse is also true. All these patients were counselled in the preoperative setting about the nature of surgery, advantages, disadvantages approach of surgery, conversion possibility and long term outcome. The risk of barrettes esophagus in three of our patients who were resistant to medical management was explained to them. A formal consent was obtained from the patients.

In our study, median age was 40 years (range 20-70 years) and there are 5 male patients and 3 female patients and median weight was 70 kg (range 60-105 kg). There was a noticeable lack of data on the demographic group in the study conducted previously. Mean operative time was 90 minutes (range 70-120), the operating time decreased with experience. The operating time was comparable to the study conducted by David I Watson, with mean Operative time of 81 minutes (range 45-154) minutes. Two patients developed symptoms of bloating, early satiety, nausea and diarrhea. These symptoms improved within weeks and responded to appropriate medication.

The mean hospital stay was 3.5 days (range 3-6 days) and mean follow was 6 months (range 1 month-1 year) this was comparable to study

Table 1. Shows variables and there results

Variable	Results
Age (years)	40 (20-70)
Sex	Male=5, Female=3
Median weight(kgs)	70 (60-105)
Mean Operative time(minutes)	90 (60-120)
Post operative pain	Minimal
Intra and postoperative complication	
Bleeding	0
Esophageal perforation	0
Diaphragmatic injury	0
Vagal nerve injury	0
Conversion to open	0
Post operative fever	1
Port site infection	1
Mean hospital stay (Days)	3.5(3-6)
Recurrence of symptoms	0
Mean Follow up	6 (1-12 months)

conducted by David I Watson with mean hospital stay of 3 days (rang 3 -8 days) and follow up 5 months rang (1 month 1 year).

In our study the results demonstrated excellent symptomatic out come with shorter operative time , hospital stay, early discharge and early return to normal physical activity and also cost effective, as well as beneficial to patients by reducing the morbidity of surgery [19], with no reduction in efficacy. One of our patients in this series developed postoperative fever which responded to usual analgesics prescribed. One more patient developed port site infection which settled within first 10 days of surgery performed. We didn't have any conversions to open technique and we followed them for around 1 year.

5. CONCLUSION

We conclude from our early series of 8 cases, that patients having long standing GERD not responding to medical management who are at a threat to develop barrettes esophagus should be given the benefit of laparoscopic fundoplication. Patients having CT documented hiatus hernia are also indications for laparoscopic fundoplication. Laparoscopy gives them all the benefits of minimal access surgical procedure and avoids a big laparotomy on them. However proper evaluation, patient's selection is mandatory. The choice of fundoplication should be dictated by the surgeon's preference and experience. Currently, the main indication for laparoscopic fundoplication is represented by PPI-refractory GERD, provided that objective evidence of reflux

as the cause of ongoing symptoms has been obtained by impedance-pH monitoring.

CONSENT

It is not applicable.

ETHICAL APPROVAL

The approval from the ethics committee and a signed informed consent were obtained from the patients.

COMPETING INTERESTS

Authors have declared that no competing interests exist.

REFERENCES

1. Kahrilas PJ, Shaheen NJ, Vaezi MF. American gastroenterological association institute technical review on the management of gastroesophageal reflux disease. *Gastroenterology*. 2008;135:1392–1413, 1413-1-5. [PubMed] [Google Scholar]
2. Stefanidis D, Hope WW, Kohn GP, Reardon PR, Richardson WS, Fanelli RD. Guidelines for surgical treatment of gastroesophageal reflux disease. *Surg Endosc*. 2010;24:2647–2669. [PubMed] [Google Scholar]
3. Katz PO, Gerson LB, Vela MF. Guidelines for the diagnosis and management of gastroesophageal reflux disease. *Am J Gastroenterol*. 2013;108:308–328,329. [PubMed] [Google Scholar]

4. Vakil N, van Zanten SV, Kahrilas P, Dent J, Jones R. The montreal definition and classification of gastroesophageal reflux disease: A global evidence-based consensus. *Am J Gastroenterol.* 2006;101:1900–1920,1943.
5. Spechler SJ, Sharma P, Souza RF, Inadomi JM, Shaheen NJ. American Gastroenterological Association technical review on the management of Barrett's esophagus. *Gastroenterology.* 2011;140:18-52,13.
6. Fitzgerald RC, di Pietro M, Ragnauth K, Ang Y, Kang JY, Watson P, Trudgill N, Patel P, Kaye PV, Sanders S, et al. British society of gastroenterology guidelines on the diagnosis and management of Barrett's oesophagus. *Gut.* 2014;63:7–42.
7. Nissen R. Eine einfache operation zur beeinflussung der reflux oesophagitis. *Schweiz Med Wochenschr* 1956;86:590-2.
8. Nissen R. Gastropexy and fundoplication in surgical treatment of hiatus hernia. *Am J Dig Dis.* 1961;6:954-61.
9. DeMeester TR, Bonavina L, Albertucci M. Nissen fundoplication for gastroesophageal reflux disease. *Ann Surg.* 1986;204:9-20.
10. DeMeester TR, Stein HJ. Minimizing the side effects of antireflux surgery. *World J Surg* 1992;16:335-6.
11. Siewert JR, Feussner H, Walker SJ. Fundoplication: How to do it? Periesophageal wrapping as a therapeutic principle in gastro-esophageal reflux prevention. *World J Surg.* 1991;16:326-44.
12. Luostarinen MES, Isolauri J, Laitinen J, Koskinen M, Keyrilainen O, Markkula H, et al. Fate of Nissen fundoplication after twenty years. A clinical, endoscopic and functional analysis. *Gut.* 1993;34:1015-20.
13. Sifrim D, Zerbib F. Diagnosis and management of patients with reflux symptoms refractory to proton pump inhibitors. *Gut.* 2012;61:1340–1354.
14. Kahrilas PJ, Howden CW, Hughes N. Response of regurgitation to proton pump inhibitor therapy in clinical trials of gastroesophageal reflux disease. *Am J Gastroenterol.* 2011;106:1419–1425,1426.
15. Stein HJ, DeMeester TR. Surgical management of esophageal disorders. *Curr Opin Gastroenterol.* 1992;8:613-23.
16. Dallemagne B, Weerts JM, Jehaes C, Markiewicz S, Lombard R. Laparoscopic nissen fundoplication: Preliminary report. *SurgLaparoscEndosc.* 1992;1:138-43.
17. Geagea T. Laparoscopic Nissen's fundoplication: preliminary report on ten cases. *Surg Endosc.* 1991;5:170-3.
18. Falk GL, Brancatisano RP, Hollinshead J, Moulton J. Laparoscopic fundoplication: A preliminary report of the technique and post-operative care. *Aust NZJ Surg.* 1992; 62:969-72.
19. Warshaw AL. Reflections on laparoscopic surgery. *Surgery.* 1993;114:629-30.

© 2019 Chalkoo et al.; This is an Open Access article distributed under the terms of the Creative Commons Attribution License (<http://creativecommons.org/licenses/by/4.0>), which permits unrestricted use, distribution, and reproduction in any medium, provided the original work is properly cited.

Peer-review history:

*The peer review history for this paper can be accessed here:
<http://www.sdiarticle3.com/review-history/49996>*